

# Comparison of SPECT/CT and Planar Imaging Following Radiosynovectomy

Filiz Özülker\*, Müjdat Adaş\*\*, Mehmet Tarık Tatoğlu\*\*\*, Ebru Özgönel\*\*\*\*, Tamer Özülker\*

\*Okmeydanı Eğitim ve Araştırma Hastanesi, Nükleer Tıp Kliniği, \*\*Ortopedi Kliniği, \*\*\*Medeniyet Üniversitesi, Nükleer Tıp Kliniği, \*\*\*\*Bilim Üniversitesi Nükleer Tıp Anabilim Dalı

## ABSTRACT

**Objective:** We aimed to compare the efficacies of SPECT/CT and planar imaging of joints after radiosynovectomy.

**Material and Methods:** Six patients with hemophylic arthropathy (HA) (5 hemophilia A, 1 hemophilia B) with a mean age 10.5 (range between 8-15) underwent radiosynovectomy in our clinic between January 2004-December 2012. Postradiosynovectomy planar and SPECT-CT imaging of 5 knee joints, 1 elbow joint and two ankle joints were obtained.

**Results:** Distribution pattern of activity showed no difference between SPECT/CT and planar imaging methods. In one patient there was loculation of activity in suprapatellar recess detected with SPECT/CT which was not delineated in planar image.

**Conclusion:** Addition of SPECT/CT to the postradiosynovectomy imaging protocol might help in identification of those who are at risk for potentially serious local complications.

**Keywords:** extraarticular leakage, radiosynovectomy, SPECT/CT

## ÖZ

**Radyosinovektomi Sonrası SPECT/BT ve Planar Görüntülemenin Karşılaştırılması**

**Amaç:** Radyosinovektomi sonrası eklemlerin planar ve SPECT/BT görüntülemelerinin etkinliklerini karşılaştırmayı amaçladık.

**Gereç ve Yöntemler:** Ocak 2004-Aralık 2012 arasında hemofilik artropatili 6 hastaya kliniğimizde radyosinovektomi uygulandı. 5 diz, 1 dirsek ve 2 ayak bileği eklemine radyosinovektomi sonrası planar ve SPECT/BT görüntülemesi yapıldı.

**Bulgular:** SPECT/BT ve planar görüntüleme yöntemleri arasında aktivitenin dağılım paterni değişim göstermedi. Bir hastada suprapatellar reseste SPECT/BT ile planar görüntülemeye görülemeyen aktivite lokulasyonu görüldü.

**Sonuç:** Postradyosinovektomi görüntüleme protokollerine SPECT/BT'nin eklenmesi lokal komplikasyonlar gelişme riski bulunan hastaların belirlenmesinde yararlı olabilir.

**Anahtar kelimeler:** ekstraartiküler kaçak, radyosinovektomi, SPECT/BT

## INTRODUCTION

Radiosynovectomy (RS) is a proven important technique which has been used efficiently as a local form of radiotherapy to control resistant synovitis and recurrent hemarthrosis. It was first introduced by Fellingner et al. (1) in 1952 and has been used successfully for 60 years as an alternative to surgery for treatment of chronic synovitis of patients in whom systemic antiinflammatory medications, intraarticular steroid and chemical injections don't provide relief (2-6). The indications of treatment with 90Y-Silicate/citrate, 186Re-sulfide, 32P-chromic phosphate or 169Er-citrate are (7): RA, undifferentiated arthritis characterized by

synovitis, inflammatory joint diseases of other origin (Lyme's borreliosis, psoriatic arthritis, ankylosing spondylitis), persistent synovial effusion (e.g., after endoprosthesis placement), osteoarthritis characterized by synovitis, villonodular synovitis, and hemarthrosis and synovitis associated with hemophilia.

The proposed mechanism of action is selective destruction of the pathologic synovium by  $\beta$ -emitting radionuclide-loaded colloidal particles which are taken up by the type-A synoviocytes through phagocytosis (8). Extraarticular leakage of radionuclide and consequent radiation exposure of periarticular tissues, lymph nodes and liver is one of the possible

Alındığı Tarih: 06.03.2016

Kabul Tarihi: 22.03.2016

Yazışma adresi: Uzm. Dr. Filiz Özülker, Belkıs Konakları Şehit Tevfik İnan Sok. E33, Uskumruköy 34450 İstanbul  
e-posta: fozulker@gmail.com

complications of the procedure. In order to prevent this, for radiolabelling, choosing an appropriate colloid particle size which is small enough to be phagocytized but not so small that it might leak from the joint before being phagocytized is important. Posttreatment imaging should be done to confirm the homogenous distribution of the radionuclide in the intra-articular cavity and to detect any possible leakage. For this purpose whole-body and static images are obtained by registering bremsstrahlung in energy window  $70\text{keV}\pm 15\%$  for  $^{90}\text{Y}$  and  $\gamma$ -rays in energy window  $137\text{keV}\pm 15\%$  for  $^{186}\text{Re}$ . Planar imaging has the drawback of poor spatial resolution, so we added SPECT/CT to our postradiosynovectomy imaging protocol, with the hope of getting better detection of extraarticular leakage and evaluation of intraarticular distribution pattern of radionuclide.

## MATERIALS and METHODS

Thirty patients with hemophylic arthropathy (HA) (22 hemophilia A, 8 hemophilia B) with a mean age of  $13.2\pm 3.2$  (range 9-21) underwent radiosynovectomy in our clinic between January 2004-December 2012. We administered 148-185 MBq Yttrium 90 silicate ( $^{90}\text{Y}$ ) (CIS, Gif-Sur-Yvette Cedex, France) to 28 knee joints and 74 MBq Rhenium 186 ( $^{186}\text{Re}$ ) (CIS, Gif-Sur-Yvette Cedex, France) to 4 ankle and 1 elbow joints. Patients who met the following prerequisites were enrolled for radiosynovectomy application: (1) more than four hemorrhagic episodes in six months (2) at least a Stage II haemophilic arthropathy according to the classification of Arnold and Hilgartner (3) persistent synovitis. All decisions were given in our hemophilic arthropathy council composed of an expert orthopedist, pediatric hematologists, a nuclear medicine specialist and a physiotherapist. All patients were admitted to the hospital and treated with factor replacement so as to raise the factor level of the patient to 80% the following morning and 50% for three days thereafter. Factor VIII (Hemofil M, Eczacibasi-Baxter, Istanbul, Turkey) or Factor IX (Immunine, Eczacibasi-Baxter) complexes were used for factor replacement. The effusion in the joint was evacuated before the injection of the radiocolloid. Intraarticular injection in ankle joint was done under fluoroscopic guidance. After the injection, the needle was flushed with a small volume of saline and the needle was withdrawn. The joint was moved rapidly

a few times to make sure the homogenous distribution of the radiocolloid, after which a plaster of paris cast was applied for 72 hours. Two hour after the RS, planar images of the treated joints and the regional lymph nodes were obtained with gamma camera by using brehmstrahlung rays of  $^{90}\text{Y}$  and gamma rays of  $^{186}\text{Re}$  to confirm the appropriate distribution of the radionuclide in the joint. Six patients out of the 30 (5 hemophilia A, 1 hemophilia B) with a mean age of 10.5 (range between 8-15) additionally underwent single photon emission computed tomography-computed tomography (SPECT-CT) imaging of 5 knee joints, 1 elbow joint and two ankle joints. The distribution pattern of radionuclide in joint on both Planar and SPECT-CT imaging was scored as i) diffuse, ii) predominantly diffuse but also focal, iii) predominantly focal but also diffuse and iv) focal<sup>(9)</sup>. The follow-up of patients were done by getting MRI and X-ray images of the joints 6 months after RS. The clinical assessment of the efficacy of the RS was made with the comparison of the average bleedings before and after the intervention by evaluating the patients at 6 month intervals. Differences in bleeding frequency between the measurements done before and after the RS were examined for statistical significance using the Wilcoxon signed rank test. The results were considered significant when p value was  $<0.05$ .

## RESULTS

Among 30 patients, the median number of bleedings was mean  $3\pm 1,1$  during the 6 months period before the injection and mean  $1\pm 1,1$  during the 6 months following RS. The marked decrease in the frequency of hemorrhages was statistically significant ( $p<0.05$ ). In the patient group who underwent SPECT/CT, the mean frequency of hemorrhages of the joints were  $1.6\pm 0.9$  and  $0.3\pm 0.6$  per month before and after RS, respectively ( $p<0.05$ ). Distribution pattern of activity showed no difference between SPECT/CT and planar imaging methods. In one patient there was loculation of activity in suprapatellar recess detected with SPECT/CT which was not delineated in planar image.

## DISCUSSION

Although RS is a rather safe procedure when properly applied, radiation synovitis, tissue necrosis and infection as a result of inadequate injections are among

the possible complications of RS. There are also controversial long term side effects like development of early degenerative joint alterations, development of neoplasms and chromosomal damage. Although, acute lymphoblastic leukemia (ALL) was reported in a child within the following year after RS<sup>(10)</sup>, the correlation was not strong and no increase in cancer incidence was shown in studies with large series that have been made to search for any possible relationship between RS and development of malignancies<sup>(11,12)</sup>. Theoretically RS might have genotoxic effect as a result of extraarticular leakage of radioactivity and whole body irradiation, but researches made concerning this potential adverse effect showed that RS does not induce the genotoxic effects on the peripheral blood lymphocytes in the paediatric population<sup>(13-16)</sup>.

Müller-Brand reported only one case of serious local radiation necrosis among 983 joints treated with RS<sup>(17)</sup>. This complication might be seen either as a consequence of extraarticular leakage of the radionuclide or backflash through the puncture tract. Rivard et al detected percentage of extra-articular radioactivity as 0.1-14% among 71 RS procedures<sup>(11)</sup>. The amount of this leakage might be as much as 25%<sup>(18)</sup>.

There have been several methods tried to image the intra-articular distribution of radionuclide as well as visualising any associated leakage. Coya-Viña et al proposed using metastable Technetium-99 (<sup>99m</sup>Tc)

in conjunction with the <sup>90</sup>Y and <sup>186</sup>Re injection and tried to show the distribution of the injected isotope indirectly by capturing the images of gamma-emitting isotope<sup>(19)</sup>. Twenty-four-hour urine collections were obtained to monitor any possible extraarticular leakage but this procedure was left since there was not any detectable radioactivity in urine<sup>(11)</sup>. Y-90 decay scheme includes a minor branch to the production of positrons and this enabled positron emission tomography (PET) imaging for accurate localisation of Y-90 microspheres following hepatic embolisation therapy. There are also few studies on the detection of extraarticular leakage and intraarticular distribution of radionuclides in RS procedures with PET imaging. It has been reported that PET imaging following <sup>90</sup>Y radiation synovectomy is feasible and can provide superior image quality compared with bremsstrahlung imaging and may enable reliable detection of extra-articular Y-90 activity when there are focal patterns on planar bremsstrahlung imaging<sup>(20,21)</sup>. Today the most commonly used method in postradiosynovectomy imaging is obtaining planar images with gamma camera by registering bremsstrahlung for <sup>90</sup>Y and  $\gamma$ -rays for <sup>186</sup>Re. In our study group we added SPECT/CT imaging to the planar imaging protocol in 6 patients. Although there was no difference between SPECT/CT and planar imaging in terms of distribution pattern, SPECT/CT detected loculation of activity in suprapatellar recess which was not located in planar image (Figure 1 and Figure 2). Nonhomogenous distribution

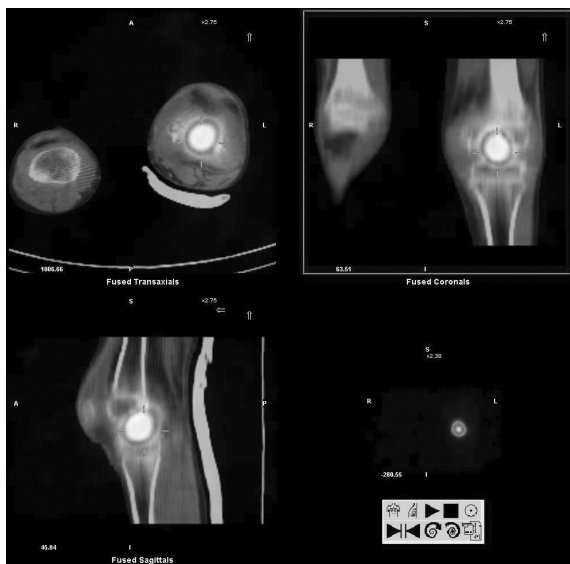


Figure 1. Axial, coronal and sagittal SPECT/CT images showing focal accumulation of Y-90 in the left knee joint of a patient.

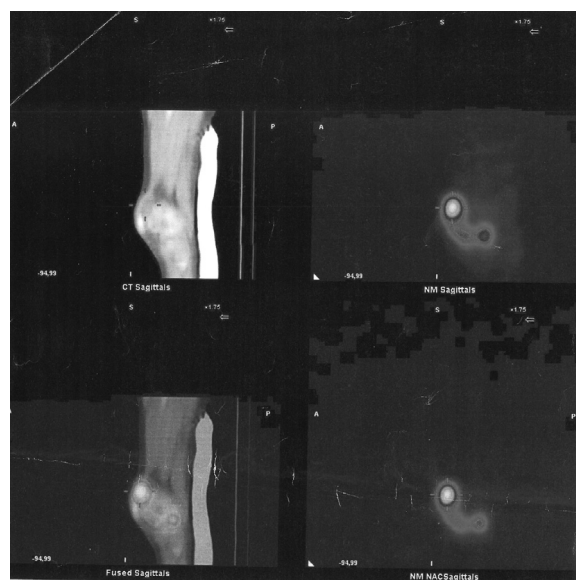


Figure 2. Axial, coronal and sagittal SPECT/CT images showing focal accumulation of Y-90 in the suprapatellar recess of a patient.

of radionuclide in joint was seen with a prevalence of 46% in one study<sup>(9)</sup>. The loculation of the activity in the joint space is probably due to intra-articular septa or large synovial folds. Up to now no association between intra-articular distribution of <sup>90</sup>Y and the clinical effect of the RSO was detected<sup>(9,22)</sup>.

The main limitation of our study is the small number of patients but the results suggest us that implementation of SPECT/CT in the postradiosynovectomy imaging protocol might help in identification of those who are at risk for potentially serious local complications. Further studies should be made to understand whether SPECT/CT can contribute to determination of those who are unlikely to respond to treatment by detection of extraarticular leakage and intraarticular distribution pattern.

## REFERENCES

1. Fellingner K, Schmid J. Die lokale Behandlung der rheumatischen Erkrankungen. *Wien Z Inn Med* 1952;33(9):351-63.
2. Bridgman JF, Bruckner F, Bleehen NM. Radioactive yttrium in the treatment of rheumatoid knee effusion. *Ann Rheum Dis* 1971;30(2):180-2. <http://dx.doi.org/10.1136/ard.30.2.180>
3. Bussina I, Toussaint M, Ott H, Hermans P, Fallet GH. A double-blind study of <sup>169</sup>erbium synoviorthesis in rheumatoid digital joints. *Scand Rheumatology* 1979;8(2):71-4. <http://dx.doi.org/10.3109/03009747909105339>
4. Deutsch E, Brodack JW, Deutsch KF. Radiation synovectomy revisited. *Eur J Nucl Med* 1993;20(11):1113-27. <http://dx.doi.org/10.1007/BF00173494>
5. Kavakli K, Aydoğdu S, Omay SB, et al. Long-term evaluation of radioisotope synovectomy with Yttrium 90 for chronic synovitis in Turkish haemophiliacs: Izmir experience. *Haemophilia* 2006;12(1):28-35. <http://dx.doi.org/10.1111/j.1365-2516.2005.01175.x>
6. Kavakli K, Aydoğdu S, Taner M, et al. Radioisotope synovectomy with rhenium186 in haemophilic synovitis for elbows, ankles and shoulders. *Haemophilia* 2008;14(3):518-23. <http://dx.doi.org/10.1111/j.1365-2516.2008.01691.x>
7. Schneider P, Farahati J, Reiners C. Radiosynovectomy in rheumatology, orthopedics, and hemophilia. *J Nucl Med* 2005;46:48-54.
8. Ingrand J. Characteristics of radio-isotopes for intra-articular therapy. *Ann Rheum Dis* 1973;32(Suppl 6): Suppl: 3-9.
9. Jahangier ZN, van der Zant FM, Jacobs JW, et al. The intra-articular distribution of <sup>90</sup>yttrium does not influence the clinical outcome of radiation synovectomy of the knee. *Ann Rheum Dis* 2007;66(8):1110-2. <http://dx.doi.org/10.1136/ard.2005.047373>
10. Turkmen C. Safety of Radiosynovectomy in Hemophilic Synovitis: it is time to re-evaluate!. *Journal of Coagulation Disorders* 2009;www.slm-respiratory.com.
11. Rivard GE, Girard M, Be' langer R, et al. Synoviorthesis with colloidal P32 chromic phosphate for the treatment of hemophilic arthropathy. *J Bone Joint Surg Am* 1994;76(4):482-8.
12. Vuorela J, Sokka T, Pukkala E, Hannonen P. Does yttrium radiosynovectomy increase the risk of cancer in patients with rheumatoid arthritis? *Ann Rheum Dis* 2003;62(3):251-3. <http://dx.doi.org/10.1136/ard.62.3.251>
13. Kavakli K, Cogulu O, Aydoğdu S, et al. Long-term evaluation of chromosomal breakages after radioisotope synovectomy for treatment of target joints in patients with haemophilia. *Haemophilia* 2010;16(3):474-8.
14. Kavakli K, Cogulu O, Karaca E, et al. Micronucleus evaluation for determining the chromosomal breakages after radionuclide synovectomy in patients with hemophilia. *Ann Nucl Med* 2012;26(1):41-6. <http://dx.doi.org/10.1007/s12149-011-0540-9>
15. Turkmen C, Ozturk S, Unal SN, et al. Monitoring the genotoxic effects of radiosynovectomy with Re-186 in paediatric age group undergoing therapy for haemophilic synovitis. *Haemophilia* 2007;13(1):57-64. <http://dx.doi.org/10.1111/j.1365-2516.2006.01406.x>
16. Turkmen C, Ozturk S, Unal SN, et al. The genotoxic effects in lymphocyte cultures of children treated with radiosynovectomy by using yttrium-90 citrate colloid. *Cancer Biother Radiopharm* 2007;22(3):393-9. <http://dx.doi.org/10.1089/cbr.2006.328>
17. Müller-Brand J. Principles of radiosynoviorthesis. *Schweiz Med Wochenschr* 1990;120(18):676-9.
18. Deutsch E, Brodack JW, Deutsch KF. Radiation synovectomy revisited. *Eur J Nucl Med* 1993;20(11):1113-27. <http://dx.doi.org/10.1007/BF00173494>
19. Coxa-Vi-a J, Martin-Ferrer M, Martin-Curto LM. Radiactive isotopes for radiosynoviorthesis. In: Rodriguez-Merchan EC, ed. *The Haemophilic Joints: New Perspectives*. Wiley-Blackwell, Oxford, 2003:181-6.
20. Thomas W, Barber, Kenneth S. K. Yap, Victor Kalff. PET/CT imaging of <sup>90</sup>Y radiation synovectomy. *Eur J Nucl Med Mol Imaging* 2012;39(5):917-8. <http://dx.doi.org/10.1007/s00259-011-2058-8>
21. Barber TW, Yap KS, Cherk MH, Powell A, Kalff V. Comparison of positron emission tomography/CT and bremsstrahlung imaging following Y-90 radiation synovectomy. *J Med Imaging Radiat Oncol* 2013;57(5):567-71. <http://dx.doi.org/10.1111/1754-9485.12049>
22. Teyssler P, Taborska K, Kolostova K, Bobek V. Radiosynoviorthesis in hemophilic joints with yttrium-90 citrate and rhenium-186 sulfide and long term results. *Hell J Nucl Med* 2013;16(1):44-9.