

Laryngeal Mask Airway Rupture During Wake up From General Anesthesia

Hakan Erkal , Yücel Yüce 

Clinic of Anaesthesiology and Reanimation, Kartal Dr. Lütfi Kırdar Training and Research Hospital, İstanbul, Turkey

Dear Editor,

We report a case of laryngeal mask airway (LMA) rupture during wake up from general anesthesia. LMAs have become an essential part of anesthetic procedures since their introduction into the clinical practice 30 years ago and have been a safely and commonly used equipment for airway maintenance during elective procedures under general anesthesia (1).

Despite the non-invasive nature of the device, some pharyngolaryngeal complications have been associated with it. These include sore throat; damage to the lingual, recurrent laryngeal, and hypoglossal nerves; vocal cord paralysis; alteration of taste and speech; tongue cyanosis; and swelling (2).

A 13-year-old boy received general anesthesia for correction of his strabismus with 4.5 mm medial rectus recession. He had no medical comorbidity. Written informed consent was obtained from the patient's parents, and after 6 hours of fasting, he was transferred to the operation room. General anesthesia was induced with fentanyl 2 µg/kg and propofol 2.5 mg/kg; for the facilitation of LMA insertion, rocuronium (0.6 mg/kg) was administered, and LMA (size 3) was inserted at first attempt. Anesthesia was maintained using sevoflurane in oxygen and nitrous oxide mixture. The patient was stable during the surgery. At the 40 min of the operation, after the administration of a neuromuscular agent (0.2 mg/kg), the surgeon indicated the completion of the surgery. For fast recovery, sugammadex (2 mg/kg) was administered to the patient without spontaneous ventilation, 30 s after which the patient suddenly woke up and became agitated. He bit LMA, which tore into two parts, and his oxygen saturation dropped to 93%. A facemask with oxygen was, thus, applied. He maintained spontaneous breathing but did not open his mouth. We administered 20 mg propofol at that time; with the aid of LMA pilot tube and aspiration tube, the distal half of LMA was pulled out from his mouth. The oral structures of the patient and the structural integrity of LMA were intact, and there were no missing pieces (Figure 1). The patient recovered with no adverse effects.

Laryngeal mask airway is commonly and safely used in ophthalmic surgeries (3). However, the use of neuromuscular blockers at LMA replacement or during the surgery is controversial (4).

Laryngeal mask airway insertion instructions recommend the use of bite blocks to prevent patients from biting on LMA as they wake up from anesthesia. Unfortunately, many anesthetists often overlook the use of bite blocks.

In patients in whom neuromuscular blockers are used, acetylcholinesterase antagonists do not allow a rapid reversal of profound neuromuscular blockade, whereas sugammadex has the potential for this type of reversal, with the return of muscle activity occurring in less than 2 min compared with that with neostigmine (5). With removal of the neuromuscular agent effects, protective reflexes with muscle strength and biting can appear.

Tracking the number of uses is essential to preventing the overuse of a reusable LMA. Continued use of LMA airways beyond 40 uses increases the probability of device malfunctions.

ORCID IDs of the authors:
H.E. 0000-0001-7439-5322;
Y.Y. 0000-0003-0396-1248

Cite this article as:

Erkal H, Yüce Y. Laryngeal Mask Airway Rupture During Wake up From General Anesthesia. Eur Arch Med Res 2018; 34 (3): 209-10

Corresponding Author:

Hakan Erkal

E-mail:

hakerkal@hotmail.com

Received: 21.09.2016

Accepted: 17.10.2017

DOI:10.5152/eamr.2018.46547

©Copyright 2018 by
European Archives of
Medical Research - Available
online at eurarchmedres.org

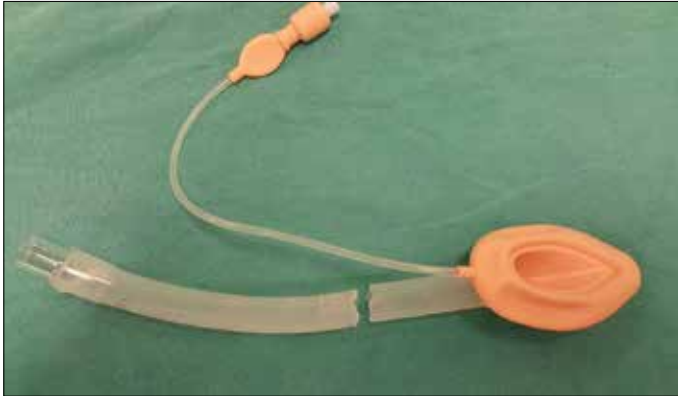


Figure 1. Fractured laryngeal mask airway with size 3

In addition, we recommend preoperative evaluation of LMA using pre-use tests prior to each use to check the structural integrity. We should use the standard insertion and fixation techniques and bite blocks during wake up procedure, especially in cases in which neuromuscular blocking agents are not used.

This complication, which can be prevented using the abovementioned measures, reinforces once again the importance of tracking the usage number of LMA recommended by the manufacturer.

Informed Consent: Written informed consent was obtained from patient's parents who participated in this case.

Peer-review: Externally peer-reviewed.

Author Contributions: Concept - H.E.; Design - H.E.; Supervision - H.E.; Resources - H.E., Y.Y.; Materials - Y.Y.; Data Collection and/or Processing - H.E., Y.Y.; Analysis and/or Interpretation - H.E., Y.Y.; Literature Search - H.E., Y.Y.; Writing Manuscript - Y.Y.; Critical Review - H.E., Y.Y.

Conflict of Interest: Authors have no conflicts of interest to declare.

Financial Disclosure: The authors declared that this study has received no financial support.

REFERENCES

1. Ramaiah R, Das D, Bhananker SM, Joffe AM. Extraglottic airway devices: A review. *Int J Crit Illn Inj Sci* 2014; 4: 77-87. [\[CrossRef\]](#)
2. Hanumanthaiah D, Masud S, Ranganath A. Inferior alveolar nerve injury with laryngeal mask airway: a case report. *J Med Case Rep* 2011; 5: 122. [\[CrossRef\]](#)
3. Choi SR, Park SW, Lee JH, Lee SC, Chung CJ. Effect of different anesthetic agents on oculocardiac reflex in pediatric strabismus surgery. *J Anesth* 2009; 23: 489-93. [\[CrossRef\]](#)
4. Hernandez MR, Klock PA Jr, Ovassapian A. Evolution of the extraglottic airway: a review of its history, applications, and practical tips for success. *Anesth Analg* 2012; 114: 349-68. [\[CrossRef\]](#)
5. Kara T, Ozbagriacik O, Turk HS, Isil CT, Gokuc O, Unsal O, et al. Sugammadex versus neostigmine in pediatric patients: a prospective randomized study. *Rev Bras Anesthesiol* 2014; 64: 400-5. [\[CrossRef\]](#)