

Synovial Response to Intraarticular Injection of Dexmedetomidine in Rats

Namigar Turgut *, Aygen Türkmen *, Aysel Altan *, Sumru Gökkaya *, Esener Baylan **, Deniz Özcan **, Zafer Berkman ***, Yersu Kapra ****

* S.B. Okmeydanı Eğitim ve Araştırma Hastanesi, Anesteziyoloji ve Reanimasyon Kliniği, ** Patoloji Kliniği, *** S.B. Haydarpaşa Numune Eğitim ve Araştırma Hastanesi, **** İstanbul Üniversitesi, Çapa Tıp Fakültesi, Patoloji Anabilim Dalı

SUMMARY

Objective: Dexmedetomidine is the pharmacologically active dextroisomer of medetomidine that displays specific and selective α_2 -adrenoceptor agonism. We have investigated the effects of intraarticular administration of dexmedetomidine in the rat knee joint.

Material and Methods: Fifty-one mature Sprague-Dawley rats were included in the study. 16.10^{-3} mol. litre⁻¹ of dexmedetomidine was injected into the right knee joint in Group I rats (n=33). Three rats were sham operated. The rats were sacrificed at 24th h (10 rats), at 48th h (10 rats) and on the 7th day (10 rats). In the second step, 16.10^{-2} mol. litre⁻¹ dexmedetomidine was administered intraarticularly in 6 rats (Group II).

Results: Histopathological findings in Group I were a regular synovial membrane at 24. hours; polymorphonuclear leucocytes, mast cells and a regular synovial membrane at 48. hours; mild polymorphonuclear leucocytes, lymphocytes and mild edema on the 7th day. These findings were indicative of a moderate inflammation. In Group II were rare leucocytes, rare lymphocytes along with plenty of mast cells, foci of microcalcifications due to localized trauma and increased leucocytes in the surrounding muscle tissue, thickening of synovial membrane and papillary proliferation on the 7th day. Findings indicative of a moderate inflammation were also encountered on the 7th day with the concentration increased 10 times.

Conclusion: Caution should be taken when using intra-articular dexmedetomidine for post-operative analgesia. According to our results, we concluded that further research is needed on this topic.

Key words: intraarticular, rat, dexmedetomidine, analgesia, synovium, cartilage

ÖZET

Ratlarda Deksmetomidinin İntraartiküler Enjeksiyonuna Sinovyal Cevap

Amaç: Spesifik ve selektif α_2 adrenoseptör agonist Deksmetomidin medetomidinin farmakolojik olarak aktif dekstroizomeridir. Çalışmamızda rat diz eklemine deksmetomidinin intraartiküler uygulanmasının etkilerini araştırdık.

Gereç ve Yöntemler: Elli Sprague-Dawley rat çalışmaya dahil edildi. Grup I ratlara (n=33) 16.10^{-3} mol. litre⁻¹ deksmetomidin sağ diz eklem içine enjekte edildi. Üç rat sham ameliyat edildi. Ratlar 48. sa. (10 rat) ve 7. gün (10 rat), 24. saat (10 rat) sakrifiye edildi. İkinci adımda ise, 16.10^{-2} mol. litre⁻¹ deksmetomidin intraartiküler verildi (Grup II), (n=6).

Bulgular: Histopatolojik bulgular Grup I'de 24. saatte; düzenli bir sinovyal membran, 48. saatte; polimorfonükleer lökositler, mast hücreleri ve düzenli bir sinovyal membran. 7. günde; hafif polimorfonükleer lökositler, lenfositler ve hafif ödem görüldü. Bu bulgular orta derecede inflamasyon gösteriydi. Grup II'de 7. günde; sinovyal membranda kalınlaşma ve papiller çoğalması, nadir lökosit, nadir lenfositler, bol mast hücreleri ile birlikte, lokalize travma ve çevresindeki kas dokusunun artmış lökosit nedeniyle mikrokalsifikasyonlar odakları görüldü. Bu bulgular konsantrasyonun 10 kat artışı ile ılımlı bir inflamasyon göstergesiydi.

Sonuç: Post-operatif analjezi için intraartiküler deksmetomidin kullanırken dikkat edilmelidir. Bu konuda daha fazla araştırma gerekli olduğu sonucuna varıldı.

Anahtar kelimeler: intraartiküler, rat, deksmetomidin, analjezi, sinovyum, kartilaj

Alındığı Tarih: 05.10.2011

Kabul Tarihi: 25.12.2012

Yazışma adresi: Doç. Dr. Namigar Turgut, S.B. Okmeydanı Eğitim ve Araştırma Hastanesi, İstanbul

e-posta: mavi.ilke@hotmail.com

INTRODUCTION

Arthroscopic knee surgery is one of the most common surgeries performed in outpatient setting; however, postoperative pain is believed to be a major barrier for early discharge and rehabilitation ⁽¹⁾. Analgesics are commonly injected intraarticularly for analgesia after arthroscopic surgery, especially of knee joints ^(2,3). For the purpose of research, non-steroidal anti-inflammatory drugs and local anesthetics were used ⁽⁴⁻⁷⁾. Studies of intra-articular (i.a.) injections of these drugs are often associated with pain modulations ^(7,8). On the other hand, the histopathological studies following i.a. administrations are a few in number and the aim of many experimental studies has been to investigate the activities of drugs in inflamed animal knees ^(9,10).

Dexmedetomidine, an imidazole compound, is the pharmacologically active dextroisomer of medetomidine that displays specific and selective α_2 -adrenoceptor agonism. The mechanism of action is unique and differs from those of currently used sedative agents, including clonidine. Although dexmedetomidine is approved for i.v., and i.m. use, no toxicological data exist regarding its i.a. administration. In this study we have investigated the effects of i.a. administration of dexmedetomidine in the rat knee joint.

MATERIALS and METHODS

Animals

The study was approved by the local ethics Committee on the Use of Live Animals in the Ministry of Health, Haydarpaşa Numune Training and Research Hospital. Fifty-one mature Sprague-Dawley rats weighing 250-300 g were included in the study. Power analysis showed that 33 and 18 subjects per study group were required.

Experimental procedure

Rats were divided into two groups. 33 rats

were included in Group I and 18 rats in Group II. All rats were anesthetized by injection of 2 mg kg⁻¹ intraperitoneal ketamine hydrochloride.

In Group I rats, under aseptic conditions, 16.10-3 mol. litre⁻¹ of dexmedetomidine (100 µg mL⁻¹ 2 mL of dexmedetomidine was diluted with 48 mL of physiological 0.9 % saline solution) was injected into the right, and 0.25 mL of physiological 0.9 % saline solution into the left. knee joints of the animals. The animals were then allowed to awake and returned to their cages. The rats were sacrificed by a lethal injection of ketamine hydrochloride at 24th h (10 rats), at 48th h (10 rats) and on the 7th days (10 rats) after the drug administration. Three rats were sham operated; and sacrificed on the first, the second, and the seventh day after this procedure. In the second step, 100 µg mL⁻¹ 2 mL of dexmedetomidine was diluted with 3 mL of physiological 0.9 % saline solution (40 µg mL⁻¹) and 16.10-2 mol. litre⁻¹ of this diluted solution was administered intraarticularly into 6 rats. Each 2 mL vial contained 18 mg NaCl and sterile water for injection. A solution including 18 mg NaCl in 50 mL was prepared and 0.25 mL of this solution was administered into 6 rats. Besides, a solution containing 18 mg NaCl in 5 mL was prepared and 0.25 mL of this solution was administered into 6 rats. These rats were sacrificed on the 7th day.

The knee joints were detached and examined for gross signs of hematoma. They were labeled accordingly (left/right, time of death, etc.), then placed in 10 % neutral buffered formalin for 4 weeks. The joints were then decalcified in 14 % EDTA for another 3 weeks, and then embedded in paraffin and processed for sectioning. Paraffin blocks were sectioned at 5 µm intervals and the prepared slides were stained with haematoxyline and eosin. Knee joints were excised, and a "blind" observer evaluated the slides for inflammation of the articular cartilage, inflammatory cell infiltration, hypertrophy, and hyperplasia of the synovial membrane.

Inflammatory changes in the joints were classified as follows:

1. No inflammation; 2. Minimal inflammation (mild congestion and edema); 3. Mild inflammation (congestion and edema, a few neutrophils); 4. Moderate inflammation (neutrophils and macrophages, synoviocytic hyperplasia); 5. Severe inflammation (neutrophils and macrophages, synovioyte hyperplasia, fibrin exudation) ⁽¹¹⁾.

Statistical analysis

Statistical analysis was performed using a computer software package (Statistical Package for Social Sciences for Windows, 10.0). Data were tested for normality by examination of histograms and by the Kolmogorov-Smirnov test and reported accordingly as mean (\pm SD) or median (range). The Mann-Whitney U test was used to calculate the probability of the differences between the experimental and control groups at 24 h, 48 h, and 7 days being attributable to chance. A $p < 0.05$ value was considered as significant.

RESULTS

There was no hematoma over the joint capsule on gross examination in control and dexmedetomidine groups. Histopathological findings in dexmedetomidine Group I were a regular synovial membrane at 24. hours (Figure 1), polymorphonuclear leucocytes, mast cells and a regular synovial membrane at 48. hours (Figure 2), mild polymorphonuclear leucocytes, lymphocytes and mild edema on the 7th day. These findings were indicative of a moderate inflammation (Figure 3). In Group II, scarce number of leucocytes, and lymphocytes along with plenty of mast cells, foci of microcalcifications due to localized trauma and increased number of leucocytes in the surrounding muscle tissue, thickening of synovial membrane and papillary proliferation on the 7th day. Findings indicative of a moderate inflammation were also encountered on the 7th with the 10-fold increase in concentration (Figure 4).

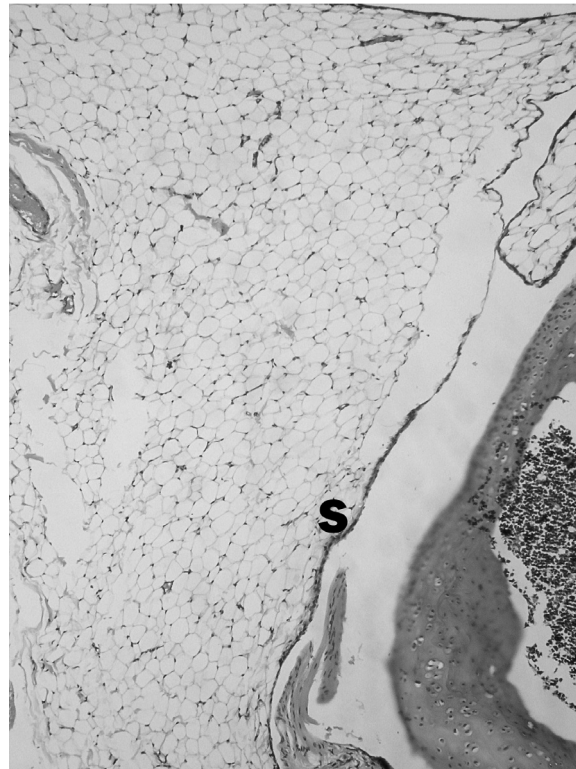


Figure 1. A regular synovial membrane at 24. hours.

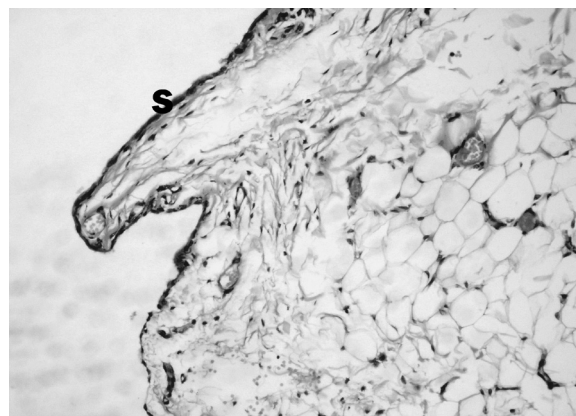


Figure 2. Polymorphonuclear leucocytes, mast cells and a regular synovial membrane at 48. Hours.

Histopathological changes were not determined in the rats which were administered a solution including 18 mg NaCl without dexmedetomidine. There were no histopathological changes in the saline-treated control joints. When the groups were compared for the degree inflammation, no significant differences for inflammatory changes were observed between the groups ($p > 0.05$) (Table 1).

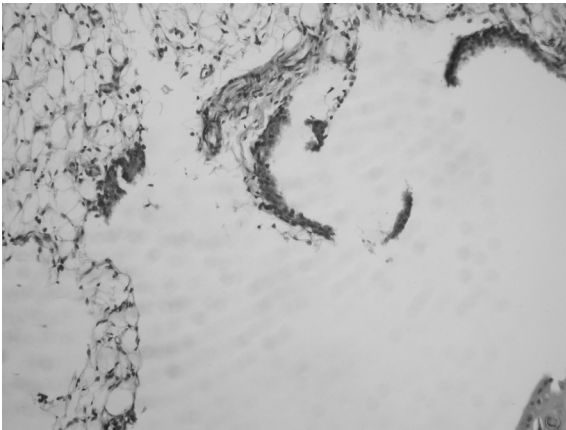


Figure 3. Mild polymorphonuclear leucocytes, lymphocytes and mild edema on the 7th day.

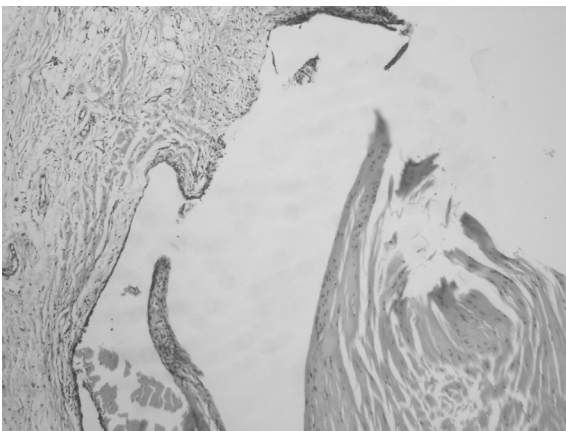


Figure 4. A moderate inflammation were also encountered on the 7th with the 10-fold increase in concentration.

Table 1. Incidence and severity of knee joint inflammation. p values were determined by comparing control and dexmedetomidine groups $p > 0.05$.

Inflammation	Group C Mean±SD	Group D Mean±SD	p
24 th h	2.40±0.51	2.60±0.51	0.383
48 th h	2.50±0.52	2.80±0.42	0.170
7 th days	2.50±0.53	2.70±0.67	0.522

DISCUSSION

The aim of this study was to evaluate the effects of i.a. use of dexmedetomidine, which is a new, potent and selective alpha₂ agonist effective on articular cartilage and synovial membrane. Arthroscopy of the knee joint is a common procedure that is routinely performed on an outpatient basis. Traditionally, oral analgesics are prescribed for the management

of postoperative pain. The routine prescription of oral opioid analgesics administered on an as-needed basis, however, frequently results in inadequate pain relief. Unrelieved postoperative pain may delay discharge from the hospital, resulting in a prolonged hospital stay, inability to participate in rehabilitation programs, delayed recovery, poor outcome, and greater use of health care resources. At present, several techniques are available to treat pain following arthroscopic knee surgery; these include the use of opioids which provide either peripherally or centrally mediated analgesia, local anesthetics, nonsteroidal anti-inflammatory drugs, corticosteroids, and clonidine⁽¹²⁻¹⁷⁾.

Recently, there is an increase trend in using anti-nociceptive drugs intra-articularly. However, pre-clinical or clinical studies performed to evaluate the local tissue toxicity of these drugs are not sufficient in number. As questioned by Buerkle, Can the i.a. analgesics be used safely without performing pre-clinical studies?⁽¹⁸⁾.

Dogan et al.⁽¹⁹⁾ studied the changes in joint synovium and cartilage caused by i.a. ketorolac and morphine. Macroscopic hematoma was observed in few rabbit joint capsules. In histopathological analysis, both groups revealed moderate cell hyperplasia or hypertrophy of synovial membrane, except ketorolac group on 24th hour. Ketorolac is a non-steroid anti-inflammatory drug (NSAID) approved only for intravenous use in USA. In this study, however, any toxic effect of its i.a. use was not observed and therefore, this route could be used safely. When studying the potential effects of Gadolinium (Gd)-DTPA-dimeglumine on synovial membrane and joint cartilage, since a minimal focal mononuclear cell infiltration was observed, its i.a. injection was considered safe⁽²⁰⁾.

Literature data showed that i.a. use of clonidine, which is another alpha₂ agonist agent, has also been studied^(21,22). Gentili et al.,⁽²³⁾ stated that i.a. clonidine has a postoperative

analgesic effect after knee arthroscopies, due to its a peripheral mechanism of action.

Although there is no data in the literature on i.a. use of dexmedetomidine, it has been used as an adjuvant medication in regional anesthesia ⁽²⁴⁾. In our study, we have observed varying degrees of synovial membrane inflammatory cell infiltration and minimal or mild synovial membrane cell hyperplasia in the dexmedetomidine group. High-dose drug administration is as important as that of standard-dose in intra-articular drug administration. Suominen et al. ⁽²⁵⁾ used i.a. bupivacaine, which is another NSAID, in their study on horses. Moderate inflammation and effusion were observed only in the high-dose group. The glycosaminoglycan concentration of articular cartilage did not change. As a result, i.a. bupivacaine was reported as a NSAID that could be used. In another study performed on rats, an increase in polymorphonuclear leukocyte level was observed four hours after administering high-dose i.a. capsaicin (capsaicin hydrochloride). Then, the number of mononuclear cells increased progressively. Therefore, high-dose capsaicin resulted in severe progressive inflammatory reaction ⁽²⁶⁾.

In another study Dogan et al. ⁽²⁷⁾ demonstrated that when i.a. neostigmine and bupivacaine were injected in combination into the articular cartilage, a severe inflammation occurred. Same results are valid for local anesthetics, as well. As we know, i.a. local anesthetics are frequently used in the treatment of postoperative surgical pain. They are administered in high concentrations however, their neurotoxic and myotoxic effects can not be excluded. In a study of Pietruck, ⁽²⁸⁾ lidocaine and bupivacaine have been found to have anti-inflammatory and analgesic properties in lower concentrations with a lesser degree of toxicity. Other i.a. drugs administered most frequently are the COX-2 inhibitors. Parecoxib alone has no effect on cartilage and synovium of normal rats' knees. It has shown inhibitory effects on the cartilage degeneration. In addition to its anti-inflammatory effects,

it has been shown to inhibit excitatory amino acid release ⁽²⁹⁾. In other studies, all COX-2 inhibitors significantly reduced joint swelling. In conclusion, the selective inhibition of COX-2 may result in the amelioration of synovitis with a lowered risk of NSAID-induced cartilage damage in rheumatic disease ⁽³⁰⁾.

In our study, we administered two different concentrations of dexmedetomidine and found the same level of mild hyperplasia and hypertrophy of synovial membrane cells even if 10-fold concentrated drug was injected. The anticipated severe and progressive reaction against high dose dexmedetomidine has not occurred. Encountering with no histopathologic changes in the rats which received injections of a solution including 18 mg NaCl without dexmedetomidine demonstrated that the inflammation was a side effect of dexmedetomidine. However, the mild inflammation was observed after injection of 10-fold increased concentration of dexmedetomidine.

Many orthopedic approaches performed arthroscopically cause moderate or severe pain. Therefore, a pain assessment and a pain treatment plan should be done. Although i.a. administration is a reliable method, its efficiency is controversial. The major reason for the controversy is the administration of such drugs without investigating their toxicological and pharmacokinetic effects in preclinical studies. Joint changes in rats may not, of course, be directly comparable to those found in humans. A direct comparison without human studies is not possible. However, Sprague-Dawley rats have often been used as a convenient animal model for toxicological studies.

Our results demonstrated that, a single i.a. injection of dexmedetomidine causes mild synovial inflammation. The effect is not dose-dependent and can be induced by relatively small doses of dexmedetomidine. According to our results, we conclude that further research is needed on this topic.

REFERENCES

1. Talu GK, Ozyalçın S, Koltka K, Erturk E, Akinci O, Asik M, Pembeci K. Comparison of efficacy of intraarticular application of tenoxicam, bupivacaine and tenoxicam: bupivacaine combination in arthroscopic knee surgery. *Knee Surg Sports Traumatol Arthrosc* 2002; 10:355-360.
<http://dx.doi.org/10.1007/s00167-002-0306-y>
PMid:12444514
2. Samoladas EP, Chalidis B, Fotiadis H, Terzidis I, Ntobas T, Koimtzis M. The intra-articular use of ropivacaine for the control of post knee arthroscopy pain. *J Orthop Surg* 2006; 23:17.
<http://dx.doi.org/10.1186/1749-799X-1-17>
PMid:17187686 PMCid:1769474
3. Elhakim M, Nafie M, Eid A, Hassin M. Combination of intra-articular tenoxicam, lidocaine, and pethidine for outpatient knee arthroscopy. *Acta Anaesthesiol Scand* 1999; 43:803-808.
<http://dx.doi.org/10.1034/j.1399-6576.1999.430804.x>
PMid:10492407
4. Elhakim M, Fathy A, Elkott M, Said MM. Intra-articular tenoxicam relieves post-arthroscopy pain. *Acta Anaesthesiol Scand* 1996; 40:1223-1226.
<http://dx.doi.org/10.1111/j.1399-6576.1996.tb05554.x>
PMid:8986186
5. Colbert ST, Curan E, O'Hanlon DM, Moran R, McCarroll M. Intra-articular tenoxicam improves postoperative analgesia in knee arthroscopy. *Can J Anaesth* 1999; 46:653-657.
<http://dx.doi.org/10.1007/BF03013953>
PMid:10442960
6. Tamosiunas R, Brazdionyte E, Tarnauskaite-Augutiene A, Tranauskaite-Keraiiene G. Postoperative analgesia with intraarticular local anesthetic bupivacaine and alpha2-agonist clonidine after arthroscopic knee surgery. *Medicina (Kaunas)* 2005; 41:547-552.
7. Garlicki J, Dorazil-Dudzic M, Wordliczek J, Przewlocka B. Effect of intraarticular tramadol administration in the rat model of knee joint inflammation. *Pharmacol Rep* 2006; 58:672-679.
PMid:17085859
8. Tran KM, Ganley TJ, Wells L, Ganesh A, Minger KI, Cucchiaro G. Intraarticular bupivacaine-clonidine-morphine versus femoral-sciatic nerve block in pediatric patients undergoing anterior cruciate ligament reconstruction. *Anesth Analg* 2005; 101:1304-1310.
<http://dx.doi.org/10.1213/01.ANE.0000180218.54037.0B>
PMid:16243985
9. Kissin EY, Freitas CF, Kissin I. The effects of intraarticular resiniferatoxin in experimental knee-joint arthritis. *Anesth Analg* 2005; 101:1433-1439.
<http://dx.doi.org/10.1213/01.ANE.0000180998.29890.B0>
PMid:16244007 PMCid:1409708
10. Zhang GH, Min SS, Lee KS, Back SK, Yoon SJ, Yoon YW, Kim YI, Na HS, Hong SK, Han HC. Intraarticular pretreatment with ketamine and memantine could prevent arthritic pain: relevance to the decrease of spinal c-fos expression in rats. *Anesth Analg* 2004; 99:152-158.
<http://dx.doi.org/10.1213/01.ANE.0000117141.76392.65>
PMid:15281522
11. Irwin MG, Cheung KMC, Nicholls JM, Thomson N. Intra-articular injection of ketorolac in the rat knee joint: effect on articular cartilage and synovium. *Br J Anaesthesia* 1998; 80:837-839.
<http://dx.doi.org/10.1093/bja/80.6.837>
PMid:9771318
12. Lombardi AV Jr, Berend KR, Mallory TH, Dodds KL, Adams JB. Soft tissue and intra-articular injection of bupivacaine, epinephrine, and morphine has a beneficial effect after total knee arthroplasty. *Clin Orthop Relat Res* 2004; 428:125-130.
<http://dx.doi.org/10.1097/01.blo.0000147701.24029.cc>
PMid:15534532
13. Vintar N, Rawal N, Veselko M. Intraarticular patient-controlled regional anesthesia after arthroscopically assisted anterior cruciate ligament reconstruction: ropivacaine / morphine / ketorolac versus ropivacaine/morphine. *Anesth Analg* 2005; 101:573-578.
<http://dx.doi.org/10.1213/01.ANE.0000158608.27411.A9>
PMid:16037178
14. Gurkan Y, Kilickan L, Buluc L, Muezzinoglu S, Tokar K. Effects of diclofenac and intra-articular morphine/bupivacaine on postarthroscopic pain control. *Minerva Anesthesiol* 1999; 65:741-745.
PMid:10598433
15. Alagol A, Calpur OU, Kaya G, Pamukcu Z, Turan FN. The use of intraarticular tramadol for postoperative analgesia after arthroscopic knee surgery: a comparison of different intraarticular and intravenous doses. *Knee Surg Sports Traumatol Arthrosc* 2004; 12:184-188.
<http://dx.doi.org/10.1007/s00167-003-0454-8>
PMid:14691621
16. Gupta A, Bodin L, Holmstrom B, Berggren L. A systematic review of the peripheral analgesic effects of intraarticular morphine. *Anesth Analg* 2001; 93:761-770.
<http://dx.doi.org/10.1097/00000539-200109000-00042>
PMid:11524353
17. Alagol A, Calpur OU, Usar PS, Turan N, Pamukcu Z. Intraarticular analgesia after arthroscopic knee surgery: comparison of neostigmine, clonidine, tenoxicam, morphine and bupivacaine. *Knee Surg Sports Traumatol Arthrosc* 2005; 13:658-663.
<http://dx.doi.org/10.1007/s00167-004-0612-7>
PMid:15912413
18. Buerkle H. Intraarticular "analgesics": are they safe? *Anesth Analg* 1999; 88:729-733.
19. Dogan N, Erdem AF, Gündoğdu C, Kursad H, Kizilkaya M. The effects of ketorolac on articular cartilage and synovium in the rabbit knee joint. *Can J Physiol Pharmacol* 2004; 82:502-505.
<http://dx.doi.org/10.1139/y04-066>
PMid:15389297
20. Hajek PC, Sartoris DJ, Gylys-Morin V, Haghghi P, Engel A, Kramer F, Neumann CH, Resnick D. The effect of intra-articular gadolinium-DTPA on synovial membrane and cartilage. *Invest Radiol* 1990; 25:179-183.
<http://dx.doi.org/10.1097/00004424-199002000-00014>
PMid:2312253
21. Reuben SS, Connelly NR. Postoperative analgesia for outpatient arthroscopic knee surgery with intra-articular clonidine. *Anesth Analg* 1999; 88:729-733.
PMid:10195512
22. Joshi W, Reuben SS, Kilaru PR, Sklar J, Maciolek H. Postoperative analgesia for outpatient arthroscopic knee surgery with intraarticular clonidine and/or morphine. *Anesth Analg* 2000; 90:1102-1106.
<http://dx.doi.org/10.1097/00000539-200005000-00018>
PMid:10781460
23. Gentili M, Juhel A, Bonnet F. Peripheral analgesic effect of intra-articular clonidine. *Pain* 1996; 64:593-596.
[http://dx.doi.org/10.1016/0304-3959\(95\)00188-3](http://dx.doi.org/10.1016/0304-3959(95)00188-3)
24. Memiş D, Turan A, Karamanlioğlu B, Pamukcu Z, Kurt I. Adding dexmedetomidine to lidocaine for intravenous regional anesthesia. *Anesth Analg* 2004; 98:835-840.
PMid:14980948
25. Suominen MM, Tulamo RM, Anttila MO, Sankari SM,

- Kiraly K, Lapvetelainen T, Helminen HJ. Effects of intra-articular injections of bupivacaine suspension in healthy horses. *Am J Vet Res* 2001; 62:1629-1635. <http://dx.doi.org/10.2460/ajvr.2001.62.1629> PMID:11592331
26. Mapp PI, Kerslake S, Brain SD, Blake DR, Cambridge H. The effect of intra-articular capsaicin on nerve fibres within the synovium of the rat knee joint. *J Chem Neuroanat* 1996; 10:11-18. [http://dx.doi.org/10.1016/0891-0618\(95\)00097-6](http://dx.doi.org/10.1016/0891-0618(95)00097-6)
27. Dogan N, Erdem AF, Erman Z, Kizilkaya M. The effects of bupivacaine and neostigmine on articular cartilage and synovium in the rabbit knee joint. *J Int Med Res* 2004; 32:513-519. PMID:15458284
28. Pietruck C, Grond S, Xie GX, Palmer PP. Local anesthetics differentially inhibit sympathetic neuron-mediated and C fiber-mediated synovial neurogenic plasma extravasation. *Anesth Analg* 2003; 96:1397-1402. <http://dx.doi.org/10.1213/01.ANE.0000060454.34258.D3> PMID:12707141
29. Jean YH, Wen ZH, Chang YC, Hsieh SP, Tang CC, Wang YH, Wong CS. Intra-articular injection of the cyclooxygenase-2 inhibitor parecoxib attenuates osteoarthritis progression in anterior cruciate ligament-transected knee in rats: role of excitatory amino acids. *Osteoarthritis Cartilage* 2006; (Epub ahead of print).
30. Gilroy DW, Tomlinson A, Greenslade K, Seed MP, Willoughby DA. The effects of cyclooxygenase 2 inhibitors on cartilage erosion and bone loss in a model of Mycobacterium tuberculosis-induced monoarticular arthritis in the rat. *Inflammation* 1998; 22:509-519. <http://dx.doi.org/10.1023/A:1022350111213> PMID:9793797