

Clinical and Radiologic Evaluation of Mucopolygen Complex on Patients Who Underwent Arthroscopic Full Thickness Supraspinatus Tendon Repair

Resul Bircan¹, Mehmet Ali Tokgöz², Tacettin Ayanoğlu³, Baybars Ataoğlu², Mustafa Özer⁴, Süha Koparal⁵, Ulunay Kanatlı²

¹University of Health Sciences Turkey, Dr. Abdurrahman Yurtaslan Ankara Oncology Training and Research Hospital, Clinic of Orthopedic and Traumatology, Ankara, Turkey

²Gazi University Faculty of Medicine, Department of Orthopedics and Traumatology, Ankara, Turkey

³Bolu Abant İzzet Baysal University, İzzet Baysal Training and Research Hospital, Clinic of Orthopedics and Traumatology, Bolu, Turkey

⁴Necmettin Erbakan University Faculty of Medicine, Department of Orthopedics and Traumatology, Konya, Turkey

⁵Ankara Bilkent City Hospital, Clinic of Radiology, Ankara, Turkey

Abstract

Objective: The use of food supplements to enhance tendon healing is increasing. This study aimed to evaluate the clinical and radiological effects of mucopolygen complex (MPC) in patients who underwent arthroscopic full-thickness supraspinatus tear repair (ASR).

Methods: Forty-six patients with ASR were divided into two groups: one receiving MPC and the other serving as a control. At 1-year follow-up, ultrasound was used to assess the supraspinatus tendon for integrity, pathology, and maximum swelling thickness. Joint function and pain were evaluated preoperatively and at follow-up using physical examination, The University of California-Los Angeles (UCLA) shoulder scale, and visual analog scale (VAS).

Results: Pathologies in the supraspinatus tendon were found in 26.1% of patients in the MPC group compared with 60.9% in the control group, a statistically significant difference ($p=0.017$). However, the mean tendon thickness did not significantly differ between the groups (5.11 mm in MPC vs. 3.87 mm in control). No significant differences were observed in pain, function, or patient satisfaction between the groups based on the UCLA and VAS scores.

Conclusion: Although MPC did not affect pain or functional outcomes in ASR patients, the lower incidence of radiological tendon pathologies and the trend toward greater tendon thickness in the MPC group suggest that MPC may promote better tendon healing. This finding supports previous findings that MPC may be beneficial for tendon repair.

Keywords: Shoulder arthroscopy, dietary supplement, supraspinatus tendon, mucopolygen complex

INTRODUCTION

Rotator cuff tendon tear (RCT) is the most common muscle-tendon rupture. Although treatment results for mild and moderate tears are successful, the success rate of treatments for severe and massive ruptures is reduced due to atrophy and

degeneration (1). Tears associated with these pathologies have re-rupture rates of up to 94% (2). Therefore, interest in improving the biomechanical and biological properties of surgical repairs continues (3). Clinical studies examining tendon-bone healing in RCTs have demonstrated that the repair tissue is significantly



Address for Correspondence: Resul Bircan, University of Health Sciences Turkey, Dr. Abdurrahman Yurtaslan Ankara Oncology Training and Research Hospital, Clinic of Orthopedic and Traumatology, Ankara, Turkey
Phone: +90 537 312 72 75 **E-mail:** resul_bircan@hotmail.com **ORCID ID:** orcid.org/0000-0002-3035-4008

Cite this article as: Bircan R, Tokgöz MA, Ayanoğlu T, Ataoğlu B, Özer M, Süha Koparal S, Kanatlı U. Clinical and Radiologic Evaluation of Mucopolygen Complex on Patients Who Underwent Arthroscopic Full Thickness Supraspinatus Tendon Repair. Eur Arch Med Res. 2024;40(3):150-154



Copyright© 2024 The Author. Published by Galenos Publishing House on behalf of Prof. Dr. Cemil Taşcıoğlu City Hospital. This is an open access article under the Creative Commons AttributionNonCommercial 4.0 International (CC BY-NC 4.0) License.

Received: 24.07.2024
Accepted: 30.09.2024

different from the natural fibrocartilaginous transition zone and it has been shown that failure occurs at this site (4,5). The aims of these studies were to prevent the formation of scar tissue by arranging the microenvironment around the repair area in order to find away to ensure optimal recovery (6). Biopsies from torn tendons show that there are a large number of apoptotic cells, and considering the low proliferative capacity of tenocyte, improving only mechanical factors is insufficient (7,8). There are reports claiming that adding stem cells to the repair site (9), implementation of intracellular or extracellular fluid components produced by bioengineering methods (10), therapeutic use of musculoskeletal growth factors (11), adding a group of cytokines and proteins that induce mitosis, extracellular matrix production, revascularization, and cell differentiation increase tendon healing. Although the theoretical effects of these cytokines and proteins have been shown, the clinical effects are still controversial.

In addition to these molecular studies, researchers reported that integrating nutritional supplement products into the normal diet had positive effects on tendon healing and tendon- bone integration. A nutritional supplement containing mucopolysaccharides (MPS), type I collagen, and vitamin C mucopolygen complex (MPC) had *in vitro* and clinical studies stating that it may be effective in tendon healing (12,13). In laboratory studies, MPC was found to impact the metabolism of tenocyte and its proliferation, which help preserve the structure of the extracellular matrix (12). Additionally, MCVC was found to stimulate the production of collagen type I and prevent the buildup of collagen type III and aggrecan, which may prevent degeneration of tendon tissue. In a study conducted on rabbits, it was shown that glucosamine chondroitin sulphate increases the tendon's adhesion to bone by increasing collagen synthesis and cell maturation (14).

The aim of this study was to evaluate the clinical and radiological effects of MPC, whose effects had previously been demonstrated under laboratory conditions, in patients who underwent arthroscopic full-thickness supraspinatus tear repair treatment.

METHODS

This study was conducted in patients who were admitted to our clinic between June 2015 and March 2016 with the complaint of chronic shoulder pain, received an arthroscopically confirmed diagnosis of isolated full-thickness supraspinatus tear, and who underwent arthroscopic rotator cuff repair.

The study was conducted in accordance with national and international guidelines concerning research on human

subjects, such as the Declaration of Helsinki. All participants provided written informed consent for their participation, and the protocol was approved by the Gazi University Clinical Research Ethics Committee. (decision number: 101, date: 22.02.2016).

Among those admitted to our clinic between the abovementioned date, a total of 46 patients with similar demographic characteristics were included. Twenty-three patients were selected as the study group and received MPC for 3 months after surgery, while the control group consisted of 23 patients that did not receive a dietary supplement. Patients with acute rupture, partial rupture, muscle atrophy (fatty infiltration), diabetes mellitus, degenerative joint pathologies, or humeral head cysts, active athletes, calcific tendinitis symptoms, pseudoparalytic or frozen shoulder symptoms; psychiatric, rheumatologic, hematological, and oncological diseases were excluded from the study.

All surgical interventions were performed by the same surgeon under 5 kg traction in the lateral decubitus position. A standard posterior portal was used for imaging, while repair was performed using the anterior and lateral portals. The supraspinatus tendon was repaired with three anchors using the double row repair technique. Acromioplasty was added to the procedure when subacromial impingement was observed in clinical and arthroscopic findings. All patients received the same postoperative physical therapy program.

In the study group, all patients were given 2 capsules of MPC (Assos Pharmaceuticals, Retendo, Istanbul, Turkey) per day, which contained 440 mg of MPS, 80 mg of type I collagen, and 60 mg of vitamin C, for 90 days. Patients were monitored regularly with visits at days 30, 60, and 90 after starting the treatment. The baseline visit was established as the day before surgical repair of the supraspinatus tendon (day 0).

Joint function was assessed at each visit and the University of California-Los Angeles (UCLA) shoulder scale was applied to each patient preoperatively and at the one year follow-up. Pain intensity was determined using visual analogue scale (VAS).

The supraspinatus tendon was characterized by ultrasound at the one year follow-up, including the situation of the tendon (re-rupture, tendinitis etc.) and thickness measurement at the point of maximum swelling. All radiographic assessments were performed by a highly experienced radiologist on musculoskeletal disorders.

Statistical Analysis

All statistical analyses were performed using IBM SPSS 24.0 software, and $p < 0.05$ was considered statistically significant.

A frequency analysis of all data was performed. For the comparison of qualitative data, Mann-Whitney U and Wilcoxon tests were used for the comparison of numerical data.

RESULTS

A total of 46 patients complied with the inclusion criteria and agreed to participate in the study. The study group consisted of 13 female and 10 male patients, whereas the control group were 15 female and 8 male patients. The mean age of the participants was 58±11.7 years for the study group, 59±6.91 years for the control group. There were no significant differences between the groups in demographic data like age, sex, etc.

When patients using MPC were compared with patients who did not; no significant difference in re-rupture was observed. However, in 73.9% of the study group, supraspinatus was observed normal (without inflammation); while only in 39.1% of the control group, supraspinatus was observed as normal (p=0.044) (Figure 1). It was found that supraspinatus lesions were statistically significantly decreased in study group patients (p=0.017) (Table 1).

The incidence of tendinosis was 8.7% and the rate of complete rupture was 4.3% in the study group, whereas the incidence of tendinosis was 39.1% and the rate of complete rupture was 13% in the control group (Figure 2). When supraspinatus thicknesses were compared between the two groups, no statistically significant difference was observed, but the difference in the mean thicknesses was considered as striking (5.11 mm study group -3.87 mm control group).

Determining differences in pain, clinical condition, and patient satisfaction between the groups was evaluated using the UCLA shoulder scale and VAS, and no statistically significant differences were observed between both groups. However, there

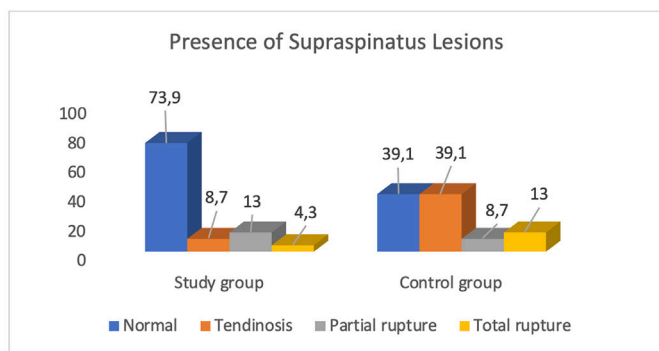


Figure 1. Graph of differences between groups in patients with supraspinatus lesion after arthroscopy

was a statistically significant difference between pre-operative scores and first-year control values in both groups (Table 2).

DISCUSSION

Failed rotator cuff repair is one of the major challenges to which an orthopedic surgeon will encounter. Although there are

Table 1. Statistical analysis of patients using mucopolygen complex and control group for supraspinatus lesion prevalence and re-rupture rate

	Study group		Control group		p*
	n	%	n	%	
Supraspinatus					
Lesion present	6	26.1	14	60.9	0.017
Lesion absent	17	73.9	9	39.1	
Supraspinatus					
Normal	17	73.9	9	39.1	0.044
Tendinosis	2	8.7	9	39.1	
Partial rupture	3	13.0	2	8.7	
Total rupture	1	4.3	3	13.0	
Re-rupture					
Present	4	17.4	5	21.7	0.710
Absent	19	82.6	18	78.3	

*: Chi-square test

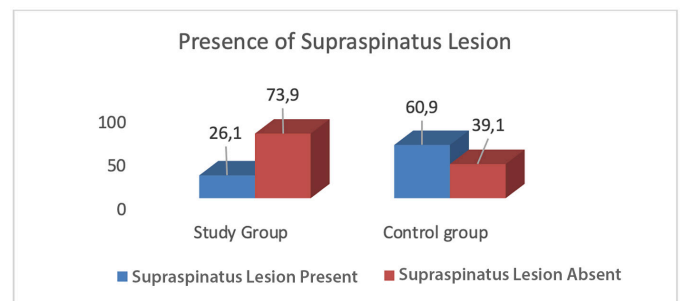


Figure 2. Graph of differences between control and study groups of lesions detected in supraspinatus after arthroscopy

Table 2. UCLA and VAS scores of patients taking mucopolygen complex and control group

	Study group	Control group	p*
	Mean (Min.-Max.)	Mean (Min.-Max.)	
Pre-op UCLA	17 (6-26)	16 (8-26)	0.523
Post-op UCLA	13 (11-22)	12 (10-20)	0.116
Pre-op VAS	6 (2-9)	6 (2-10)	0.511
Post-op VAS	2 (0-8)	2 (0-9)	0.639
Pre-post UCLA	**p=0.014	**p=0.013	
Pre-post AS	**p=0.001	**p=0.001	

*: Mann-Whitney U test, **: Wilcoxon test

UCLA: The University of California-Los Angeles, VAS: Visual analogue scale, Min.: Minimum, Max.: Maximum

different treatment strategies for retears, such as arthroscopic revision, tendon/allograft transfer, arthroplasty (15) etc. the common preference is not encountering retears in the first place.

Formulations such as food supplements, which are considered as one of the alternatives that can be used to improve tendon healing have been used increasingly. Arquer et al. (13) used MPC on patients with tendonitis at their Achilles tendon, patellar tendon, and lateral epicondyle and found that pain scores and ultrasonographic findings were statistically better in patients who did not use this complex. In another study performed by Balius et al. (16) patients with Achilles tendinopathy were divided into three groups, with two of the groups having MPC as a dietary supplement. Patients who had MPC showed statistically significantly better results for pain management. In our study, we observed that MPC did not affect the pain and functional results of operated supraspinatus tears. This was thought to be due to arthroscopic repair in all patients; hence, in the aforementioned article patients were not operated but were treated with physical therapy.

The statistically significant observation of radiological tendon pathologies (tendinitis, re-rupture) and detection of thinner supraspinatus thickness in the control groups as compared with the study group, as reported previously by other authors (12,13,17) supports the idea that the use of MPC supports tendon healing in a positive manner.

Another remarkable finding of this study is that the percentage of patients without a supraspinatus lesion in the study group was 73.9%; this ratio was calculated as 39.1% in the control group. Considering that the incidence of nutritional disorders increases with advancing age (18,19), the difference in lesion prevalence in this study can be explained by the advanced average age of the patients.

Study Limitations

The retrospective study design and sample size were the most important limitations of this study. Furthermore, the placebo effect of MPC cannot be discarded since the control group did not receive inert capsules. Ultrasonography was performed to assess the structural integrity of the healing supraspinatus because it is an objective method and cheaper compared to MRI; and performing a second-look arthroscopy or tissue biopsy is only possible for patients who need a second procedure.

CONCLUSION

In vitro studies have shown a positive effect of MPC on collagen synthesis and tenocyte proliferation, partly due to the restoration

of the microenvironment of the healing tendon; however, its working mechanism is not yet fully understood. The decreased lesion prevalence after cuff repair, as shown in this study, and the clinically positive effect on tendinopathies that were not treated surgically are promising. However, there are not enough data in the literature to make a definitive decision.

However, as the growing number of food supplement products and the increasing interest of patients are considered, this study remains important because it provides preliminary information to guide prospective randomized controlled studies with large sample sizes on the MPC.

Acknowledgments

We would also like to show our gratitude to Serkan Savlık, M.D. and İbrahim Kaya, M.D.-Gazi University for assistance in study, and Asiye Uğraş Dikmen, M.D., Gazi University for their comments that greatly improved the manuscript.

Footnote

Ethics Committee Approval: The protocol was approved by the Gazi University Clinical Research Ethics Committee. (decision number: 101, date: 22.02.2016).

Informed Consent: All participants provided written informed consent for their participation.

Authorship Contributions

Surgical and Medical Practices: R.B., U.K., Concept: R.B., M.A.T., Design: R.B., T.A., S.K., U.K., Data Collection or Processing: R.B., T.A., Analysis or Interpretation: R.B., T.A., Literature Search: B.A., M.Ö., U.K., Writing: R.B.

Conflict of Interest: No conflicts of interest were declared by the authors.

Financial Disclosure: The authors declared that this study received no financial support.

REFERENCES

1. Laron D, Samagh SP, Liu X, Kim HT, Feeley BT. Muscle degeneration in rotator cuff tears. *J Shoulder Elbow Surg.* 2012;21:164-74.
2. Zhao J, Luo M, Pan J, Liang G, Feng W, Zeng L, et al. Risk factors affecting rotator cuff retear after arthroscopic repair: a meta-analysis and systematic review. *J Shoulder Elbow Surg.* 2021;30:2660-70.
3. Mirzayan R, Weber AE, Petrigliano FA, Chahla J. Rationale for Biologic Augmentation of Rotator Cuff Repairs. *J Am Acad Orthop Surg.* 2019;27:468-78.
4. Rodeo SA. Biologic augmentation of rotator cuff tendon repair. *J Shoulder Elbow Surg.* 2007;16(5 Suppl):191-7.
5. Galatz LM, Gerstenfeld L, Heber-Katz E, Rodeo SA. Tendon regeneration and scar formation: The concept of scarless healing. *J Orthop Res.* 2015;33:823-31.

6. Patel S, Gualtieri AP, Lu HH, Levine WN. Advances in biologic augmentation for rotator cuff repair. *Ann N Y Acad Sci.* 2016;1383:97-114.
7. Anz AW, Hackel JG, Nilssen EC, Andrews JR. Application of biologics in the treatment of the rotator cuff, meniscus, cartilage, and osteoarthritis. *J Am Acad Orthop Surg.* 2014;22:68-79.
8. Chuen FS, Chuk CY, Ping WY, Nar WW, Kim HL, Ming CK. Immunohistochemical characterization of cells in adult human patellar tendons. *J Histochem Cytochem.* 2004;52:1151-7.
9. Omi R, Gingery A, Steinmann SP, Amadio PC, An KN, Zhao C. Rotator cuff repair augmentation in a rat model that combines a multilayer xenograft tendon scaffold with bone marrow stromal cells. *J Shoulder Elbow Surg.* 2016;25:469-77.
10. Kaizawa Y, Franklin A, Leyden J, Behn AW, Tulu US, Sotelo Leon D, et al. Augmentation of chronic rotator cuff healing using adipose-derived stem cell-seeded human tendon-derived hydrogel. *J Orthop Res.* 2019;37:877-86.
11. Cavendish PA, Everhart JS, DiBartola AC, Eikenberry AD, Cvetanovich GL, Flanigan DC. The effect of perioperative platelet-rich plasma injections on postoperative failure rates following rotator cuff repair: a systematic review with meta-analysis. *J Shoulder Elbow Surg.* 2020;29:1059-70.
12. Shakibaei M, Buhrmann C, Mobasheri A. Anti-inflammatory and anti-catabolic effects of TENDOACTIVE® on human tenocytes *in vitro*. *Histol Histopathol.* 2011;26:1173-85.
13. Arquer A, García M, Laucirica JA, Rius M, Blàvia M, Fontserè J, et al. The efficacy and safety of oral mucopolysaccharide, type I collagen and vitamin C treatment in tendinopathy patients. *Apunt Sport Med.* 2014;49:31-6.
14. Taşkesen A, Ataoğlu B, Özer M, Demirkale İ, Turanlı S. Glucosamine-chondroitin sulphate accelerates tendon-to-bone healing in rabbits. *Eklemler Hastalıkları Cerrahisi.* 2015;26:77-83.
15. Mannava S, Samborski SA, Kenney RJ, Maloney MD, Voloshin I. Options for Failed Rotator Cuff Repair. *Sports Med Arthrosc Rev.* 2018;26:134-8.
16. Balias R, Álvarez G, Baró F, Jiménez F, Pedret C, Costa E, et al. A 3-Arm Randomized Trial for Achilles Tendinopathy: Eccentric Training, Eccentric Training Plus a Dietary Supplement Containing Mucopolysaccharides, or Passive Stretching Plus a Dietary Supplement Containing Mucopolysaccharides. *Curr Ther Res Clin Exp.* 2016;78:1-7.
17. Fusini F, Bisicchia S, Bottegoni C, Gigante A, Zanchini F, Busilacchi A. Nutraceutical supplement in the management of tendinopathies: a systematic review. *Muscles Ligaments Tendons J.* 2016;6:48-57.
18. Agarwal E, Miller M, Yaxley A, Isenring E. Malnutrition in the elderly: a narrative review. *Maturitas.* 2013;76:296-302.
19. Guyonnet S, Rolland Y. Screening for Malnutrition in Older People. *Clin Geriatr Med.* 2015;31:429-37.