

The Effect of Radial Translation Deformity on Functional Results after the Conservative Treatment of Distal Radius Fracture

Yusuf Yahşi¹, Ömer Faruk Kümbüloğlu², Muharrem Kanar², Rodi Ertoğrul¹, Ferid Samedov², Süleyman Çakırtürk³, Hacı Mustafa Özdemir¹

¹Medipol Acıbadem District Hospital, Clinic of Orthopedics and Traumatology, İstanbul, Turkey

²University of Health Sciences Turkey, Şişli Hamidiye Etfal Research and Training Hospital, Clinic of Orthopedics and Traumatology, İstanbul, Turkey

³Afyonkarahisar State Hospital, Clinic of Orthopedics and Traumatology, Afyonkarahisar, Turkey

Abstract

Objective: Radial translation in the radiographic evaluation of distal radius fractures has recently been mentioned in the literature. The aim of this study was to evaluate the effect on clinical results of radial translation deformity following conservative treatment of radius distal fractures.

Methods: The radial translation value in the normal population was calculated by evaluating the bilateral wrist radiographs of 278 healthy individuals in the control group. The study group, a retrospective evaluation was made of 447 patients diagnosed with a distal radius fracture and treated with plaster casting. At the final follow-up examination, the wrist radiographs, DASH score, visual analog pain score (VAS), the presence of ulnar-side wrist pain, and Ballotman test results were evaluated.

Results: On the 206 wrist radiographs of the control group, the mean radial translation value was $43.6\% \pm 8.2\%$ (range: 25-66%). The mean difference between the right and left wrist measurements of the same patients was found to be $3.94\% \pm 1.64\%$. The study group included 108 patients. In patients with a radial translation difference between the two wrists of $>3.94\% \pm 1.64\%$, the DASH and VAS were significantly high ($p < 0.001$). On physical examination, distal radioulnar joint instability was determined in 78% of these patients.

Conclusion: The development of radial translation deformity after plaster cast treatment of a distal radius fracture was seen to have a negative effect on functional outcomes. Therefore, evaluation and correction of this parameter are important in the treatment of distal radius fractures.

Keywords: Radial translation, instability, distal radius fracture, deformity

INTRODUCTION

Of all the fractures in the skeletal system, 5-10% are in the forearm, and almost 75% of forearm fractures are seen at the distal radius (1). Radius distal fractures constitute approximately 16% of all the fractures seen in the emergency department (2). The parameters of ulnar variance, volar tilt, and radial inclination have long been used in the radiographic evaluation of distal radius fractures. More recently, radial translation, as another parameter, has started to be mentioned in the literature (1-3).

Radial translation is an extremely new entity defined as a shift of the distal radius in the radial direction compared to the proximal fragment (1,4). In studies conducted to date, the effect of radial translation deformity on distal radioulnar joint (DRUJ) instability was evaluated (1,2,5). However, the effects of the radial translation value on the functional results and DRUJ stability have not yet been fully clarified. The aim of this study was to evaluate the effect on clinical results of radial translation deformity developing after conservative treatment of radius distal fractures.



Address for Correspondence: Ferid Samedov, University of Health Sciences Turkey, Şişli Hamidiye Etfal Research and Training Hospital, Clinic of Orthopedics and Traumatology, İstanbul, Turkey
Phone: +90 507 347 15 97 **E-mail:** ferid.samedov@gmail.com **ORCID ID:** orcid.org/0000-0001-5555-8288

Received: 19.09.2024
Accepted: 07.10.2024

Cite this article as: Yahşi Y, Kümbüloğlu ÖF, Kanar M, Ertoğrul R, Samedov F, Çakırtürk S, Özdemir HM. The Effect of Radial Translation Deformity on Functional Results after the Conservative Treatment of Distal Radius Fracture. Eur Arch Med Res. 2024;40(3):173-178



Copyright© 2024 The Author. Published by Galenos Publishing House on behalf of Prof. Dr. Cemil Taşcıoğlu City Hospital. This is an open access article under the Creative Commons Attribution-NonCommercial 4.0 International (CC BY-NC 4.0) License.

METHODS

A control group was formed from a retrospective evaluation of the bilateral wrist posteroanterior (PA) and lateral radiographs obtained from patients aged 18-70 years who presented at the Orthopedics and Traumatology Polyclinic of Health Sciences Şişli Hamidiye Etfal Training and Research Hospital between 01.01.2014 and 01.01.2021. Patients were excluded from the study if the radiographs had not been taken in an appropriate position (6) or if the patient had a history of wrist fracture or any radiocarpal pathology in the operated wrist. Informed consent was obtained from all participants in compliance with the ethical guidelines prior to their inclusion in the study. The wrist radiographs were examined using the PACS. To perform radiographic measurements, a universally licensed application was used which has a four-point angle function and a virtual ruler. To ensure the accuracy and consistency of the measurements, the radiographs were electronically calibrated with an integral standard marker in the PACS. The radial translation values of all patients were calculated using this system. First, a line was drawn on the PA radiograph from the ulnar cortex of the radius toward the distal. A line was then drawn parallel to the distal radial joint line in the longest axis of the coronal plane of the lunate, and the point at which this line crossed the first line was identified. The length of this line on the radial side was labelled (a), and the length on the ulnar side was labelled (b) (Figure 1). The radial translation value was calculated using these lines (1,5). A retrospective evaluation was performed on the bilateral wrist radiographs of patients aged 18-70 years who were diagnosed with distal radius fracture and treated with plaster casting in the same center between 15.02.2017 and 15.02.2020. Patients were excluded if they had a fracture other than type 2R3A2 or 2R3A3 according to the association of osteosynthesis classification, if they underwent surgery because of reduction loss during follow-up, had any concomitant carpal bone fracture or ulna fracture (except ulna styloid fracture), or if the ulnar positive variance on the final follow-up images was >4mm and the radial inclination and volar tilt measurements were not within the normal limits (7). The study group was formed of patients with at least 1 year of follow-up and bilateral wrist radiographs obtained in the appropriate position at the final follow-up examination.

The patients were evaluated using the presence of ulnar-side wrist pain, Ballotman test results, and DASH and visual analogue pain scores at the final follow-up. In the Ballotman test, the presence of crepitus and pain was evaluated as DRUJ instability (4). In radiographic examination, the parameters of volar tilt, radial inclination, radial translation, and ulnar variance were

measured.

Approval for the study was granted by the Health Sciences University Şişli Hamidiye Etfal Training and Research Hospital Health Practice and Research Center Clinical Research Ethics Committee (decision number: 1980, date: 08.03.2022).

Statistical Analysis

All radiographs were evaluated by 3 observers. To determine the inter-observer agreement of the measurements obtained from the same point, the intraclass correlation coefficients (ICC) were calculated. The mean right and left measurements in the dependent groups and whether or not the differences between them were statistically significant were analyzed using the t-test. The significance of the difference between the right and left measurements in repeated measurements was examined by variance analysis. In the independent groups of variables, the difference between the mean values according to the groups was examined with the t-test. Categorical variables were analyzed using the chi-square test. The obtained data were statistically analyzed using SPSS vn. 20.0 software. The results were stated in a 95% confidence interval. A value of $p < 0.05$ was accepted as statistically significant.

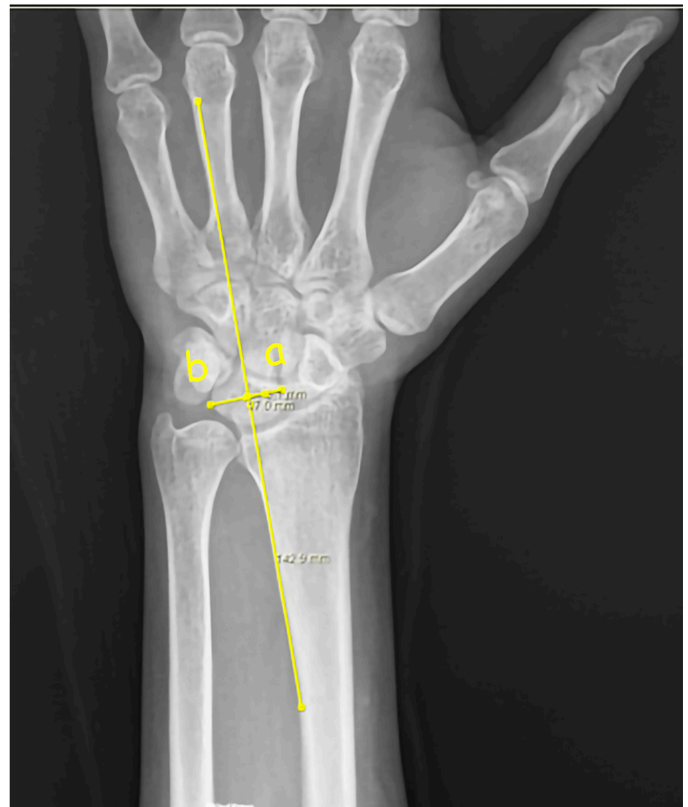

Figure 1. Radial translation value calculation: $[a / (a+b)] \times 100$

RESULTS

Control Group Results

The wrist radiographs of 278 patients were evaluated, and 103 patients who met the study criteria were included in the study. The demographic characteristics of the control group are presented in Table 1.

On the 206 wrist radiographs of the control group, the mean radial translation value was determined to be $43.6\pm 8.2\%$ (range: 25%-66%) (Figure 2). The mean difference between the right and left wrist measurements of the same patients was found to be $3.94\pm 1.64\%$.

Study Group Results

A total of 447 patients were evaluated in the study group, of which 339 did not meet the study criteria, leaving a total of 108 patients included in the study analyses. The demographic characteristics of the patients are presented in Table 2. The mean follow-up period was 21 months (range, 13-47 months). An ulna styloid fracture was found to accompany the radial distal fracture in 45% of the patients. The study group patients were

separated into two subgroups; Group A included 28 patients with ulnar positive variance of 2-4 mm, and Group B included the remaining 80 patients. Using the mean difference between the right and left wrist radial translation values ($3.94\pm 1.61\%$), the groups were separated into two groups. Patients with a difference above the mean value were named Group 1 and those with a value below the mean value, Group 2. The t-test was applied to determine whether or not the mean difference between the radial translation values of the A and B group patients was statistically significant. The mean radial translation difference was found to be 6.81 for the Group A patients and 1.41 for the Group B patients. The difference between the two groups was determined to be statistically significant ($p < 0.001$). When all patients were examined according to age, the mean age was determined to be 48.1 years in Group 2 ($n=94$) and 59.7 years in Group 1 ($n=14$). Using the t-test, the difference in mean age between the two groups was found to be statistically significant ($p < 0.001$). The mean difference in the radial translation values was found to be 1.62 in the patients aged ≤ 50 years, and statistically significantly higher at 3.53 in patients aged > 50 years ($p < 0.05$) (Table 3). The radial translation deformities of all patients based on the age group of 50 years are shown in Table 3. The mean ages of the patients was determined to be 59.7 years in Group A-1 and 45.8 years in Group A-2. When examined with the t-test, this difference between the groups was statistically significant ($p < 0.05$). The presence of DRUJ instability was evaluated statistically in the Group A patients. DRUJ instability was determined in 4 (28.5%) patients in Group 2 and in 11 (78%) patients in Group 1. The difference between the two groups was

Control group		
Mean age (years)		42.5
Gender	Male	45.6% (n=47)
	Female	54.4% (n=56)
Age groups	20-29 yrs	16.5% (n=17)
	30-39 yrs	27.2% (n=28)
	40-49 yrs	31.1% (n=32)
	50-59 yrs	13.6% (n=14)
	60-70 yrs	11.7% (n=12)
Total		103

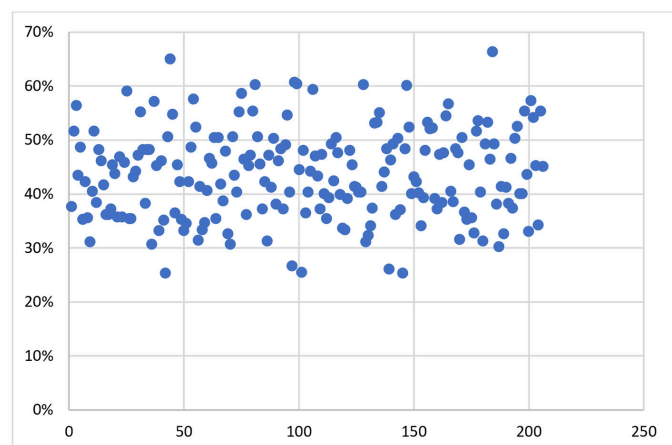


Figure 2. Distribution of the radial translation values

Study group		
Mean age (years)		49.6
Gender	Male	45.5% (n=48)
	Female	55.5% (n=60)
Side	Right	43% (n=62)
	Left	57% (n=46)
Total		108

	<50 years	≥ 50 years
Total patients (n)	41	67
A group	Group 1	9 (22%)
	Group 2	0
B group	32 (78%)	48 (71.6%)
Translation difference	1.62 ± 1.25	3.53 ± 4.47

statistically significant ($p < 0.001$). The effect of the DASH score on translation deformity in Group A patients was examined with the Independent Samples t-test. The DASH score was determined to be statistically significantly higher in the Group 1 patients than in Group 2 ($p < 0.001$) (Table 3). A significant difference was determined between these 2 groups in respect of the visual analog pain score, evaluated with the t-test, with the mean visual analog pain score of 6.36 of the Group 1 patients seen to be statistically significantly higher than that of the Group 2 patients at 3.57 ($p < 0.001$). The relationship between the presence of ulnar-side wrist pain at the final follow-up examination and the translational difference was examined using the Fisher Exact test. There was determined to be a statistically significant correlation between radial translation deformity and ulnar-side wrist pain ($p < 0.05$). The level of agreement between the measurements obtained by the 3 observers was determined with the ICC, and there was observed to be a high level of agreement ($>95\%$) between all the measurements.

DISCUSSION

The results of this retrospective study demonstrated that the mean radial translation value in the normal population was $43.6\% \pm 8.2\%$ (range: 25%-66%), and the mean difference between the right and left wrist measurements of the same patients was found to be $3.94\% \pm 1.64\%$. The DASH and visual analog scale pain scores were significantly higher in patients with a high radial translation difference than in those with lower values. The parameters of ulnar variance, volar tilt, and radial inclination have long been used in the radiographic evaluation of distal radius fractures (8). Recently, another parameter has entered the literature (1-3). In a 2008 study by Rapley et al. (9) this new parameter, which was overlooked or not diagnosed, was named ulnar translation. In 2011, Fujitani et al. (2) evaluated DRUJ instability and named this parameter radial translation. This name was subsequently accepted by different authors (1,3,5,10). Two different techniques have been defined in literature for the measurement of radial translation (1,2). In articles published in 2011 by Fujitani et al. (2) radial translation was calculated using the longest distance between the sigmoid notch and the ulnar head on PA radiographs. However, interobserver reliability was not tested in this study. The parameter of Fujitani et al. (2) increased awareness of the possibility of DRUJ instability based on radiographs obtained before reduction and presented a specific guide for the evaluation of the reduction of radial distal fractures. As the measurement this method is complex and intraoperative evaluation is difficult, Ross et al. (1) recommended another measurement method in 2014. Using this method, the

authors evaluated 100 normal wrist radiographs and found the mean radial translation rate to be $45.48\% \pm 9.6\%$ (range, 25-73.68%). This method was used in the current study, and the mean radial translation value in normal wrists was found to be $43.6\% \pm 8.2\%$ (range: 25-66%). Although the mean radial translation values obtained in these two studies were very close to each other, the range of values in both studies was extremely broad. This greatly limits the use of the mean radial translation value alone. Ross et al. (1) stated that the comparison of the radial translation value with the contralateral wrist measurement provided a more reliable result, but did not state any value related to this comparison. In the current study, the mean difference between the left and right wrist measurements was found to be $3.94\% \pm 1.64\%$, and evaluations were made according to this value. It is thought that this value could be more clearly defined in future studies with a larger population. Dario et al. (11) showed that volar tilt and ulnar variance were the primary radiographic parameters necessary for restoration to achieve the desired functional outcome in distal radius fractures. However, radial translation was not included in the radiological parameters evaluated in this study (11). In the current study of patients treated with plaster casting, there was found to be radial translation deformity in 50% of those with positive ulnar variance. Considering that this deformity could have an effect on the clinical results, it was not thought to be appropriate to evaluate the effect of ulnar positive variance on the results without evaluating radial translation. The DASH and visual analog pain scores were found to be significantly low in patients with positive ulnar variance and no radial translation compared to the patients with radial translation ($p < 0.001$). When the complaints of patients with positive ulnar variance were evaluated, there was seen to be a statistically significant negative effect. According to these results, the radial translation can be evaluated as having a negative effect on the functional results.

Although distal radius fractures are seen in every age group, the frequency is increased at older ages. However, it has been shown in the literature that impairments in the radiographic parameters of patients of advanced age have a lesser effect on functional outcomes (12). In the current study, there was seen to be a significantly greater probability of radial translation deformity developing in patients aged >50 years compared with those aged <50 years ($p < 0.05$). Further studies are needed to clarify whether the effect of this deformity on the functional results in older patients is different from that of younger patients. There are many factors involved in DRUJ stability, primarily bone anatomy, joint capsule, radioulnar ligaments, triangular fibrocartilage complex,

ulnocarpal ligaments, intraosseous membrane, and pronator quadratus muscle (4,12,13). It is accepted that impairment of the anatomic relationships between these structures can lead to DRUJ instability (4). DRUJ instability causes ulnar-side wrist pain, weakness, and loss of forearm rotation (2,14,15). Previous studies on the clinical effects of radial translation have focused on DRUJ instability. Omokawa et al. (10) found that of all the parameters on wrist PA radiographs, only the radial translation rate (with DRUJ gap length measurement) provided guidance for DRUJ instability which could develop. Ross et al. (1) reported that not correcting residual radial translation deformity could lead to DRUJ instability, which can present with the need for surgery. In the current study, DRUJ instability was observed in 78% of patients with radial translation deformity. There were some limitations to this study, primarily the retrospective design, and although interobserver reliability was statistically evaluated, intraobserver reliability was not evaluated. More analyses in future studies with larger cohorts are would be useful in the determination of the threshold value of the measurement parameter. Many different methods have been reported in the literature on the evaluation of DRUJ instability, so standardization of the methods used is extremely difficult. A further limitation could be said to be that when classifying the ulnar positive variance parameter in the measurements made, patients with an ulnar positive variance of 2-4 mm were included in the same group, and this may have had an effect on the functional results.

CONCLUSION

In conclusion, the results of this study demonstrated that when evaluating distal radius radiographs, the radial translation value should be carefully analyzed in addition to widely used parameters such as volar tilt, ulnar variance, and radial inclination. Functional impairment and DRUJ instability can develop in patients with radial translation deformity. Therefore, it is important that this parameter is evaluated and corrected in the treatment of distal radius fractures.

Footnote

This article is based on Yusuf Yahşi's thesis entitled "Radial Translasyonun Normal Değerinin Belirlenmesi ve Distal Radius Kiriği Tedavisi Sonrası Fonksiyonel Sonuçlara Etkisi" in 2022 year. Thesis Approval E-48865165-302.14.01-117229.

Ethics Committee Approval: Approval for the study was granted by the Health Sciences University Şişli Hamidiye Etfal Training and Research Hospital Health Practice and Research Center Clinical Research Ethics Committee (decision number: 1980, date: 08.03.2022).

Informed Consent: Informed consent was obtained from all participants in compliance with the ethical guidelines prior to their inclusion in the study.

Authorship Contributions

Surgical and Medical Practices: Y.Y., Ö.F.K., M.K., R.E., F.S., S.Ç., H.M.Ö., Concept: Y.Y., Ö.F.K., M.K., R.E., S.Ç., H.M.Ö., Design: Y.Y., Ö.F.K., R.E., S.Ç., H.M.Ö., Data Collection or Processing: Y.Y., R.E., F.S., S.Ç., Analysis or Interpretation: Y.Y., Ö.F.K., F.S., H.M.Ö., Literature Search: Y.Y., Ö.F.K., M.K., F.S., S.Ç., Writing: Y.Y., Ö.F.K., M.K., F.S., H.M.Ö.

Conflict of Interest: No conflicts of interest were declared by the authors.

Financial Disclosure: The authors declared that this study received no financial support.

REFERENCES

- Ross M, Di Mascio L, Peters S, Cockfield A, Taylor F, Couzens G. Defining residual radial translation of distal radius fractures: a potential cause of distal radioulnar joint instability. *J Wrist Surg.* 2014;3:22-9.
- Fujitani R, Omokawa S, Akahane M, Iida A, Ono H, Tanaka Y. Predictors of distal radioulnar joint instability in distal radius fractures. *J Hand Surg Am.* 2011;36:1919-25.
- Scott W, Wolfe, William C, Pederson, Scott H, Kozin, Mark S, Cohen. Distal Radius Fractures. In: *Green's Operative Hand Surgery.* 8th ed. Philadelphia: Elsevier; 2017. pp. 601-76.
- Dy CJ, Jang E, Taylor SA, Meyers KN, Wolfe SW. The impact of coronal alignment on distal radioulnar joint stability following distal radius fracture. *J Hand Surg Am.* 2014;39:1264-72.
- Ross M, Allen L, Couzens GB. Correction of Residual Radial Translation of the Distal Fragment in Distal Radius Fracture Open Reduction. *J Hand Surg Am.* 2015;40:2465-70.
- Schreibman KL, Freeland A, Gilula LA, Yin Y. Imaging of the hand and wrist. *Orthop Clin North Am.* 1997;28:537-82.
- Frederick Azar, S. Terry Canale, James Beaty. Fractures of the Shoulder, Arm, and Forearm. In: *Campbell's Operative Orthopaedics.* 14th ed. Philadelphia: Elsevier; 2021. pp. 3031-126.
- Pogue DJ, Viegas SF, Patterson RM, Peterson PD, Jenkins DK, Sweo TD, et al. Effects of distal radius fracture malunion on wrist joint mechanics. *J Hand Surg Am.* 1990;15:721-7.
- Rapley JH, Kearny JP, Schrayner A, Viegas SF. Ulnar translation, a commonly overlooked, unrecognized deformity of distal radius fractures: techniques to correct the malalignment. *Tech Hand Up Extrem Surg.* 2008;12:166-9.
- Omokawa S, Iida A, Fujitani R, Onishi T, Tanaka Y. Radiographic Predictors of DRUJ Instability with Distal Radius Fractures. *J Wrist Surg.* 2014;3:2-6.
- Dario P, Matteo G, Carolina C, Marco G, Cristina D, Daniele F, et al. Is it really necessary to restore radial anatomic parameters after distal radius fractures? *Injury.* 2014;45(Suppl 6):21-6.
- Gofton WT, Gordon KD, Dunning CE, Johnson JA, King GJ. Soft-tissue stabilizers of the distal radioulnar joint: an in vitro kinematic study. *J Hand Surg Am.* 2004;29:423-31.

13. Ward LD, Ambrose CG, Masson MV, Levaro F. The role of the distal radioulnar ligaments, interosseous membrane, and joint capsule in distal radioulnar joint stability. *J Hand Surg Am.* 2000;25:341-51.
14. Lindau T, Adlercreutz C, Aspenberg P. Peripheral tears of the triangular fibrocartilage complex cause distal radioulnar joint instability after distal radial fractures. *J Hand Surg Am.* 2000;25:464-8.
15. Cole DW, Elsaidi GA, Kuzma KR, Kuzma GR, Smith BP, Ruch DS. Distal radioulnar joint instability in distal radius fractures: the role of sigmoid notch and triangular fibrocartilage complex revisited. *Injury.* 2006;37:252-8.