



Comparison of Open Versus Closed Partial Nail Plate Excision with Partial Matrixectomy in Ingrown Toenail

 Remzi Çaylak

Private Ortopedia Hospital, Clinic of Orthopedics and Traumatology, Adana, Turkey

Abstract

Objective: Ingrown toenail (Onychocryptosis); caused by the nail plate growing into the lateral/medial nail fold is a common health problem characterized by pain, exudation, and granulation tissue formation. In advanced cases, partial/total nail plate excision and matrixectomy were performed. This study aimed to compare the clinical results of open versus closed partial nail plate excision and surgical partial matrixectomy in ingrown toenails.

Methods: We compared the results of patients who underwent open (n=51) or closed (n=44) partial nail plate excision and surgical partial matrixectomy by two surgeons with the diagnosis of ingrown toenails in our hospital between 2016-2021 and had at least a 1-year follow-up. The recurrence, wound problems, time to return to work/school, general and cosmetic satisfaction of the cases were examined.

Results: No recurrence was observed in either group. Wound problem/superficial infection was observed in 3 cases in the open matrixectomy group. Return to work/school was 17.8 ± 2.7 days in the open surgery group, while it was 14.4 ± 1.4 days in the closed group ($p < 0.001$). While the general satisfaction of the patients was the same in both groups, their cosmetic satisfaction was higher in the closed group (4.8 ± 0.4 vs. 4.2 ± 0.7) ($p < 0.001$).

Conclusion: Partial nail plate excision and surgical partial matrixectomy are effective and safe methods in ingrown nails. A closed procedure might increase cosmetic satisfaction as well as reduce the time to return daily activities.

Keywords: Ingrown toenail, partial nail plate excision, partial matrixectomy

INTRODUCTION

The ingrown toenail (Onychocryptosis) is a common condition characterized by pain, exudation and swelling in the nail fold (1,2). It is frequently encountered in young adults, and its frequency is increasing (3). A study conducted in Australia showed that more than 20% of surgeries for the feet were performed for ingrown toenails (4). Excessive perspiration, improper nail trimming, trauma, tight shoes, and socks play a role in the etiology (5). The growth of the nail plate into the adjacent nail fold damages the soft tissue and causes an inflammatory reaction characterized by excessive granulation tissue formation (1,2). Exudation and pain

caused by the disease can cause obstacles in the use of shoes, and as a result, problems in social and work life (1,2).

In the treatment of ingrown toenails, while conservative approaches are sufficient in the early stages, surgical approaches may be necessary in advanced stages and in recurrent cases (1,2,6-10). Conservative treatments aim to protect the nail fold from the nail plate, thus preventing secondary infections and relieving pain. Various measures, such as the use of appropriate shoes, cutting nails straight instead of round, and the treatment of concomitant hyperhidrosis and onychomycosis, must be applied at the beginning (1,2). Various non-surgical methods



Address for Correspondence: Remzi Çaylak, Private Ortopedia Hospital, Clinic of Orthopedics and Traumatology, Adana, Turkey

Phone: +90 322 432 77 77 **E-mail:** rcaylak@gmail.com **ORCID ID:** orcid.org/0000-0002-2926-4590

Cite this article as: Çaylak R. Comparison of Open Versus Closed Partial Nail Plate Excision with Partial Matrixectomy in Ingrown Toenail. Eur Arch Med Res 2023;39(1):20-25

©Copyright 2023 by the University of Health Sciences Turkey, Prof. Dr. Cemil Taşcıoğlu City Hospital
European Archives of Medical Research published by Galenos Publishing House.

Received: 22.04.2022

Accepted: 29.07.2022

such as placing cotton or dental floss under the nail plate, placing a gutter splint on the ingrown part of the nail plate, and wire applications can be used in patients who cannot achieve adequate recovery with these methods (1,2,7,8,11). Surgical treatment methods are used in advanced and/or recurrent cases.

Although many surgical techniques have been reported for ingrown toenails, a generally accepted method could not be established. The methods in the literature have advantages and disadvantages in terms of ease of application, complications, recurrence and cosmetic appearance. The ideal method should be easy to apply, have low complications and recurrence risk, as well as provide an acceptable cosmetic appearance. Partial nail plate excision with/without partial matrixectomy (surgical or chemical), total nail plate excision with/without total matrixectomy, which can be applied in stubborn cases, are the surgical alternatives that can be preferred (9,12,13).

In our hospital, the preferred surgical method for ingrown toenails is partial nail plate excision and surgical partial matrixectomy. This can be done with open or closed methods. In the open method, germinal matrix excision is made via an incision in the proximal nail fold. In the closed method, germinal matrix excision is made through the space formed by the excised nail plate. Potentially less wound problems but more recurrences can be expected with the closed method.

The aim of our study was to compare the results of open versus closed partial nail plate excision and surgical partial matrixectomy.

METHODS

Patients and Study Design

Ethics Committee approval was obtained before the study (Cukurova University, 08.04.2022, no: 121).

Patients who were treated by two different orthopedics and traumatology specialists (RÇ and ÇÖ) with the diagnosis of ingrown toenails in our hospital between January 2016 and January 2021 and had at least one year of follow-up were evaluated retrospectively. Patients who had previously undergone surgical treatment for ingrown toenails and patients with a diagnosis of diabetic foot were excluded from the study. All patients were treated with surgical partial nail plate excision and partial matrixectomy. One of the surgeons preferred the open and the other closed methods.

According to the information obtained from the hospital records, ingrown toenails were classified according to the Mozena classification (14) (Table 1). Information on whether a wound

problem developed during the follow-ups, wound healing time, time to return to work/school, recurrence and/or re-intervention was obtained from the hospital records. In addition, the patients were contacted by phone and their satisfaction with the appearance of the toe and nail after recovery and their general satisfaction were questioned. Their satisfaction was grouped between 1 to 5. It was classified as; very satisfied as 5, satisfied as 4, moderate satisfied as 3, dissatisfied as 2, and not satisfied at all as 1.

Surgical Methods

Partial nail plate excision and closed surgical partial matrixectomy method

After the sterile preparation of the foot, the procedure was performed under digital block anesthesia with 4-6 mL of 2% prilocaine. Bleeding control was achieved by circular placement of a Penrose drain on the proximal phalanx. The nail plate and nail bed were excised with a lancet 2-3 mm from the medial/lateral to the nail fold by cutting straight up to the distal phalanx longitudinally (Figure 1A-E). The germinal matrix of the nail was excised with a scalpel and curette from the space formed by the excision of the nail plate and nail bed (Figure 1F). Excision of the nail fold was not performed unless there was excessive granulation tissue. The gap between the nail fold and the remaining nail plate was approximated with 3.0 monofilament sutures (Figure 1H). The tourniquet was opened and the toe was wrapped with a non-tight dressing. Infection prophylaxis was administered with oral antibiotics for 72 hours after the procedure. The first dressing change was done 48 hours after the procedure. The dressing was renewed at 72-hour intervals until the 12th day when the sutures were removed in patients without wound problems.

Partial nail plate excision and open surgical partial matrixectomy method

After the sterile preparation of the foot, the procedure was performed under digital block anesthesia with 4-6 mL of 2% prilocaine. Bleeding control was achieved by circular placement

Stage	Signs and symptoms
1	Erythema, slight edema, and pain when pressure is applied to the lateral fold
2a	Increased stage I symptoms, drainage and infection, nail fold less than 3 mm
2b	Increased stage I symptoms, drainage and infection, nail fold 3 mm or greater
3	Magnified stage II symptoms, presence of granulation tissue and nail fold hypertrophy

of a Penrose drain on the proximal phalanx. The proximal nail plate was reached by making an incision at an angle of approximately 45 degrees to the proximal nail fold (Figure 2A, B). The ingrown lateral/medial part of the nail plate was excised by cutting it longitudinally with scissors (Figure 2C, D). The germinal matrix and proximal nail bed were excised up to the bone with a scalpel (Figure 2E, F). The area was curetted to ensure that the germinal matrix was completely excised (Figure 2G). Excision of the nail fold was not performed unless there was excessive granulation tissue. The incision in the proximal nail fold was sutured with 3.0 monofilament sutures. The gap between the nail fold and the remaining nail plate was approximated with 3.0 monofilament sutures (Figure 2H). The tourniquet was opened and the toe was wrapped with a non-tight dressing. Infection prophylaxis was administered with oral antibiotics for 72 hours after the procedure. The first dressing change was done 48 hours after the procedure. The dressing was renewed at 72 hour intervals until the 12th day when the sutures were removed in patients without wound problems.

Statistical Analysis

Categorical variables were expressed as numbers and percentages, whereas continuous variables were summarized as mean and standard deviation and as the median and interquartile range (IQR) where appropriate. The chi-square test was used to compare the categorical variables between the groups. The normality of distribution for continuous variables was confirmed with the Shapiro-Wilk test. To compare continuous variables between two groups, the Student's t-test or Mann-Whitney U test was used depending on whether the statistical hypotheses were fulfilled. All analyses were performed using the IBM SPSS Statistics Version 20.0 statistical software package. The statistical level of significance for all tests was considered 0.05.

RESULTS

While 44 toes of 36 patients (15 females, 21 males) were treated with the closed method, 51 toes of 39 patients (11

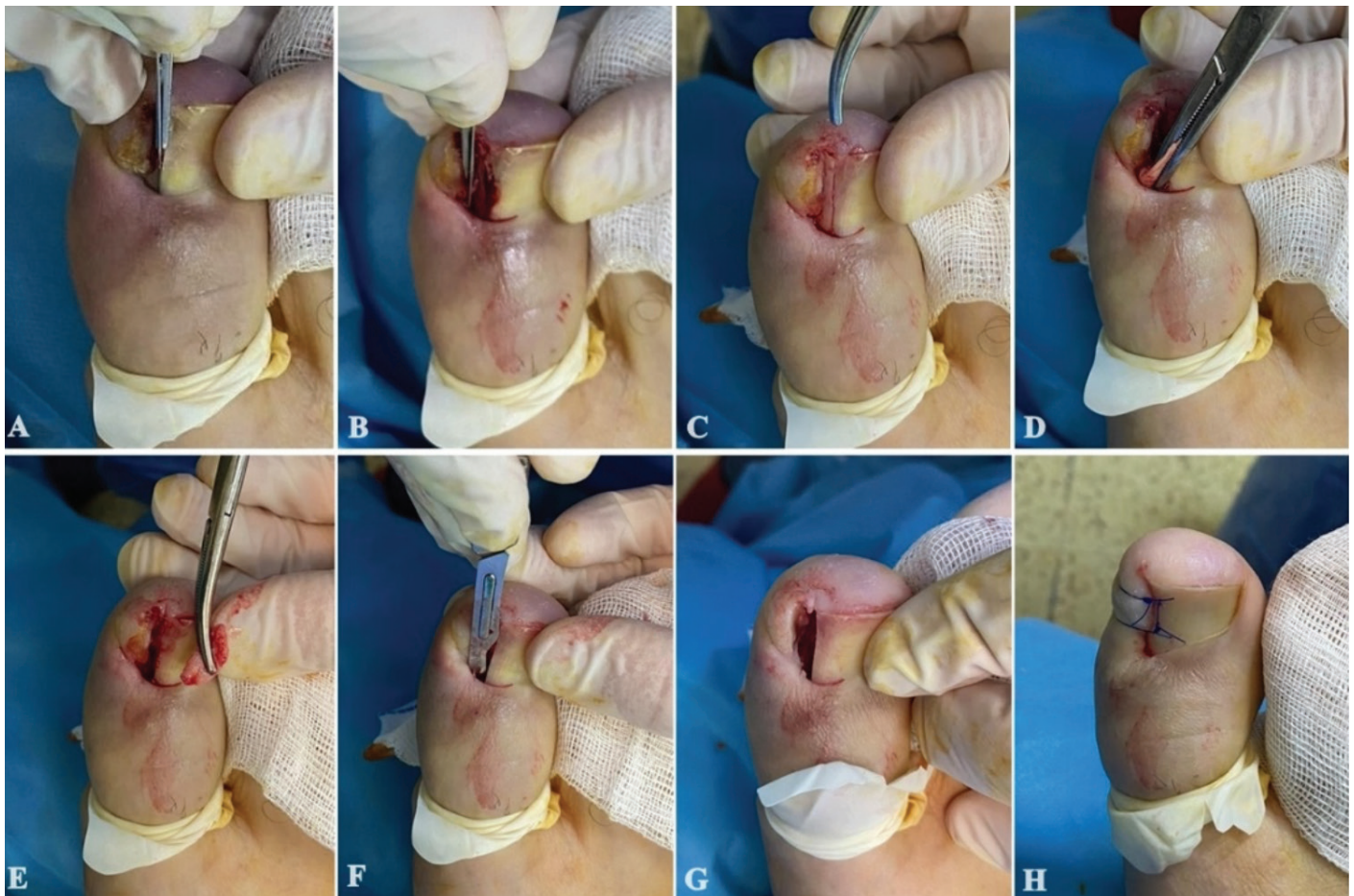


Figure 1. Partial nail plate excision and closed partial surgical matrixectomy steps. Partial excision of the ingrown part of the nail plate with the nail bed (A-E), debridement of the germinal matrix with the aid of a scalpel and curette (F-G), approximation of the nail fold to the nail plate with 3.0 monofilament sutures (H)

females, 28 males) were treated with the open method (Table 2). Eight patients in the closed method and 12 patients in the open method received bilateral ingrown toenails treatment in the same session. The median follow-up time was 29 (IQR: 36) months in the closed method and 44 (IQR: 25) months in

	Groups		p
	Closed (n=44)	Open (n=51)	
Age, mean \pm SD	23.1 \pm 13.6	24.8 \pm 10.2	0.508
Gender, Female (%)	18 (41%)	16 (31%)	0.334
Male (%)	26 (59%)	35 (69%)	
Follow-up, months, median (IQR)	29 (36)	44 (25)	0.036
Mozena class, n (%)			0.457
2a	6 (14%)	10 (20%)	
2b	19 (43%)	16 (31%)	
3	19 (43%)	25 (49%)	

SD: Standard deviation, IQR: Interquartile range

the open method. The follow-up time was longer in the open method ($p=0.036$). The median age was 19 (IQR: 17.5) years in the closed method and 22 (IQR: 20) years in the open method ($p=0.147$). There was no difference in the pre-treatment Mozena class between the groups. In the closed group, 6 (14%) ingrown toenails were 2a, 19 (43%) ingrown toenails were 2b and 19 (43%) ingrown toenails were 3, while in the open group 10 (20%) ingrown toenails were 2a, 16 (31%) ingrown toenails were 2b, and 25 (49%) ingrown toenails were 3 according to the Mozena classification ($p=0.457$).

In the follow-ups, no wound problem/infection was observed in the closed treatment group, whereas wound problem/superficial infection was observed in 3 toes in the open group ($p=0.024$). All of these cases were treated with dressing and oral antibiotics, no new surgical procedure was needed. While the patients in the closed method returned to work/school in an average of 14.4 ± 1.4 days, the patients in the open method were able to return to work/school in 17.8 ± 2.7 days ($p<0.001$).

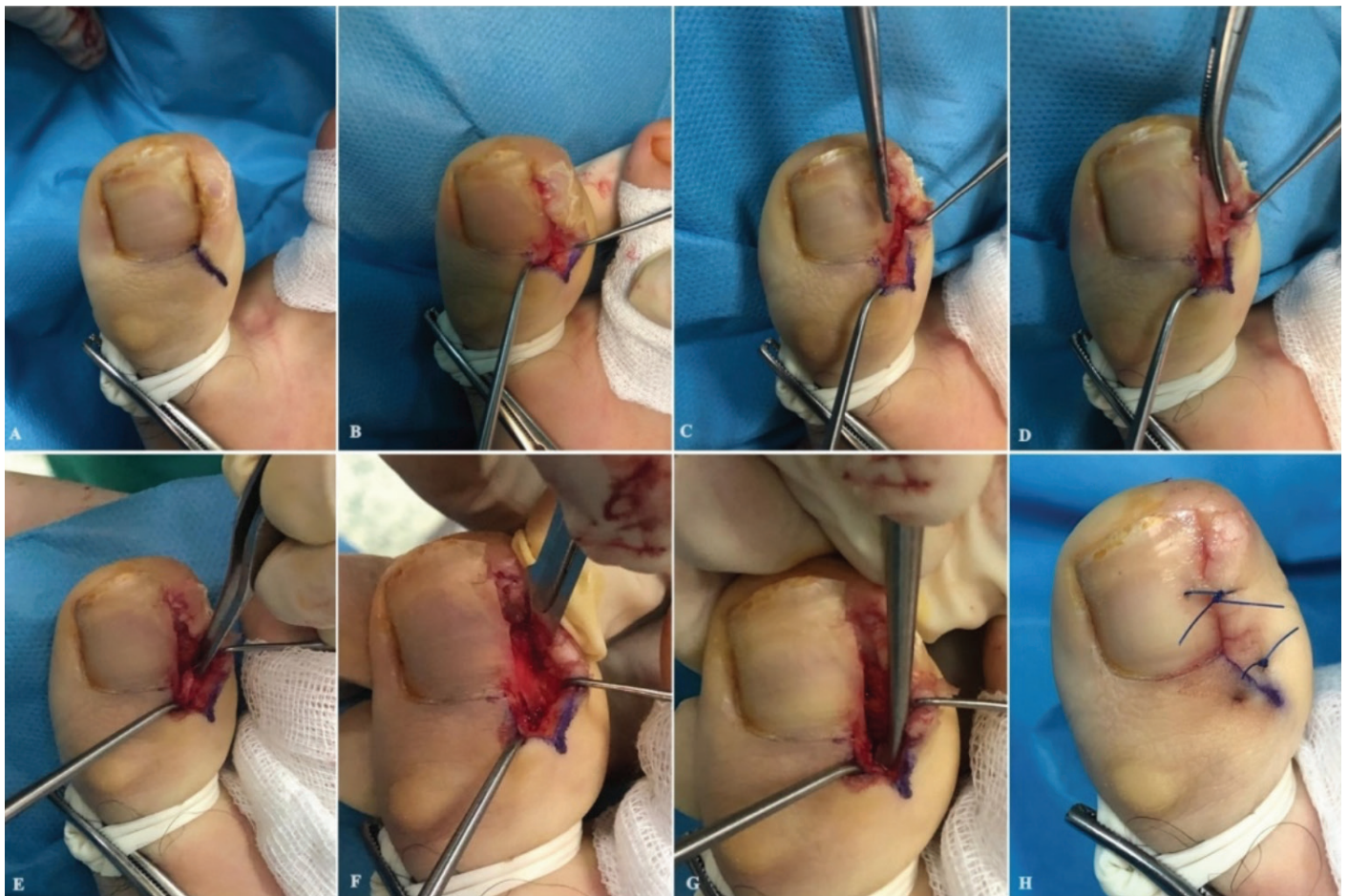


Figure 2. Partial nail plate excision and open partial surgical matrixectomy steps. Reaching the proximal nail plate and germinal matrix with an incision made at a 45 degree angle to the proximal nail fold (A, B), excision of the lateral/medial ingrown part of the nail plate with scissors (C, D), excision of the germinal matrix forming the ingrown nail plate together with the nail bed (E, F), curette debridement of the germinal matrix (G), suturing of the incision in the proximal nail fold, and approximation of the lateral/medial nail fold to the nail plate (H)

When the final cosmetic satisfaction of the toes was examined, it was 4.8 ± 0.4 in the closed group and 4.2 ± 0.7 in the open group ($p < 0.001$). Overall satisfaction was 4.7 ± 0.5 and 4.5 ± 0.6 in closed and open groups, respectively ($p = 0.145$). While there was a significant difference between the groups in terms of cosmetic appearance satisfaction, there was no difference in overall satisfaction (Table 3).

DISCUSSION

In our study, no recurrence was observed in either open or closed matrixectomy groups. However, a wound problem was observed in 3 cases who underwent open surgery. Although all 3 cases were treated with dressings and antibiotics, soft tissue infection also had the potential to develop osteomyelitis and total loss of the nail. In addition, the mean return to daily activities after wound healing in the closed method was shorter.

One of the complications of ingrown toenails is the deterioration of the cosmetic appearance of toes due to granulation tissue formation. In addition, open partial matrixectomy may cause scar tissue formation. In our study, satisfaction with the cosmetic appearance was higher in the group with closed matrixectomy. In both groups, patients were equally satisfied with overall satisfaction. However, cosmetic satisfaction was higher in the closed surgery group. Based on these advantages, a closed method might be recommended for ingrown toenail.

The ingrown toenail, also known as onychocryptosis, is a common health problem that can seriously affect the activities of daily living. While exudation and pain may limit the use of shoes, granulation tissue that develops in advanced cases may cause cosmetic dissatisfaction (1,2). In the early stages, treatment can be provided by methods such as placing cotton or dental floss under the ingrown nail plate, a hot water bath, and a gutter splint (1,2,7,8,11). In advanced stages, surgical treatment methods are preferable. The aim of surgical methods is to prevent the nail fold from disturbing the nail plate permanently. For this purpose, total/partial nail plate excision with/without matrixectomy can

be performed together (9,12,13). Matrixectomy can also be performed surgically, chemically (phenol), and by cryotherapy (10-13). The ideal treatment method should be simple, provide permanent healing, have a low complication rate, provide fast recovery, and create a good cosmetic appearance at the end of the treatment.

Partial nail plate excision with partial surgical matrixectomy has been a successful treatment method for a long time. It is frequently preferred due to the fact that the procedure can be performed with local anesthesia and the complication and recurrence rates are low (10-13). Misiak et al. (13) compared the cases that underwent phenol matrixectomy and electrocautery matrixectomy with partial nail plate excision and found 21.6% recurrence. Recurrence was more common in electrocautery matrixectomy (26.6% vs. 16.6%). Muriel-Sánchez et al. (15) reported that recurrence in patients who underwent phenol matrixectomy varied with the duration of phenol, and that increasing the duration of application reduced recurrence. However, Kim et al. (10) stated that chemical matrixectomy may cause uncontrolled damage to the soft tissue surrounding the germinal matrix, which may lead to infection, drainage and prolongation of healing (10). Bostancı et al. (16) stated that agents applied during chemical matrixectomy may cause nail dystrophy and discoloration. Barreiro et al. (17) recommended hydrogel application to protect the soft tissues around the germinal matrix from the caustic effect of phenol in cases that underwent phenol matrixectomy. Partial nail plate excision with partial matrixectomy can also be performed surgically. The aim of partial nail plate excision in surgery is to remove the ingrown nail plate from the nail fold. Regeneration of the nail plate causing the ingrowing is permanently prevented owing to excise the germinal matrix. Matrixectomy can be performed via open or closed methods. Performing it open theoretically makes it possible to completely remove the part of the germinal matrix that is desired to be excised. However, poor blood circulation of the proximal nail fold where the skin incision is made increased the likelihood of wound complications. In the literature, recurrence rates of partial nail plate excision with partial matrixectomy range from 0% to 15% (11,18-20). In the publication of Unal and Yuksekdağ (21) with the highest number of cases in the literature (2.118 cases), the recurrence rate was reported at 1.7%. The risk of recurrence in surgical matrixectomy increases in elderly patients and relapsed cases (13,21). In our study, no recurrence was observed in either group. However, no wound complications were observed in the closed surgery group, whereas those were observed in three patients in the open surgery group. In addition, cosmetic satisfaction after the

	Groups		p
	Closed (n=44)	Open (n=51)	
Wound problems, n (%)	0 (0%)	3 (6%)	0.246
Cosmetic satisfactions, mean \pm SD	4.8 ± 0.4	4.2 ± 0.7	<0.001
General satisfactions, mean \pm SD	4.7 ± 0.5	4.5 ± 0.6	0.145
Back to work/school time, mean \pm SD	14.4 ± 1.4	17.8 ± 2.7	<0.001
SD: Standard deviation			

treatment was higher in the closed surgery group. Therefore, closed surgery may be preferred, especially in patients with high cosmetic expectations.

The weaknesses of our study are that it was retrospective, the patients were not randomly selected, and the procedures were performed by different surgeons. In addition, the relatively small number of patients and the fact that it has not been compared with other treatment methods prevents it from forming a general opinion about the success of the method. Large, prospective studies are needed on the adequacy of the method.

CONCLUSION

Partial nail plate excision and surgical closed partial matrixectomy is a method that can be preferred with low complication and low recurrence rates in the treatment of patients in advanced-stage ingrown toenails. In addition, other advantages are that the cosmetic appearance does not deteriorate after the treatment and that it provides a quick return to normal daily activities.

ACKNOWLEDGMENTS

Thanks to Çağrı Örs, MD for his contributions to the preparation of the article.

Ethics

Ethics Committee Approval: Ethics Committee approval was obtained before the study (Cukurova University, 08.04.2022, no: 121).

Informed Consent: Retrospective study.

Peer-review: Externally peer-reviewed.

Financial Disclosure: The author declared that this study received no financial support.

REFERENCES

1. Thakur V, Vinay K, Haneke E. Onychocryptosis - decrypting the controversies. *Int J Dermatol* 2020;59:656-69.
2. Mayeaux EJ Jr, Carter C, Murphy TE. Ingrown toenail management. *Am Fam Physician* 2019;100:158-64.
3. Cho SY, Kim YC, Choi JW. Epidemiology and bone-related comorbidities of ingrown nail: a nationwide population-based study. *J Dermatol* 2018;45:1418-24.
4. Terrill AJ, Green KJ, Salerno A, Butterworth PA. Risk factors for infection following ingrowing toenail surgery: a retrospective cohort study. *J Foot Ankle Res* 2020;13:48.
5. Haneke E. Controversies in the treatment of ingrown nails. *Dermatol Res Pract* 2012;2012:783924.
6. Eekhof JA, Van Wijk B, Knuistingh Neven A, van der Wouden JC. Interventions for ingrowing toenails. *Cochrane Database Syst Rev* 2012;18:CD001541.
7. Senapati A. Conservative outpatient management of ingrowing toenails. *J R Soc Med* 1986;79:339-40.
8. Woo SH, Kim IH. Surgical pearl: nail edge separation with dental floss for ingrown toenails. *J Am Acad Dermatol* 2004;50:939-40.
9. Karacan E, Ertilav D. Comparison of Vandenbos procedure or Winograd method for ingrown toenail. *Jt Dis Relat Surg* 2021;32:414-9.
10. Kim J, Lee S, Lee JS, Won SH, Chun DI, Yi Y, et al. A minimally-invasive, simple, rapid, and effective surgical technique for the treatment of ingrown toenails: a reminder of the original Winograd procedure. *Int J Environ Res Public Health* 2021;18:278.
11. Peyvandi H, Robati RM, Yegane RA, Hajinasrollah E, Toossi P, Peyvandi AA, et al. Comparison of two surgical methods (Winograd and sleeve method) in the treatment of ingrown toenail. *Dermatol Surg* 2011;37:331-5.
12. Huang JZ, Zhang YJ, Ma X, Wang X, Zhang C, Chen L. Comparison of wedge resection (Winograd procedure) and wedge resection plus complete nail plate avulsion in the treatment of ingrown toenails. *J Foot Ankle Surg* 2015;54:395-8.
13. Misiak P, Terlecki A, Rzepkowska-Misiak B, Wcisło S, Brocki M. Comparison of effectiveness of electrocautery and phenol application in partial matrixectomy after partial nail extraction in the treatment of ingrown nails. *Pol Przegl Chir* 2014;86:89-93.
14. Mozena JD. The Mozena classification system and treatment algorithm for ingrown hallux nails. *J Am Podiatr Med Assoc* 2002;92:131-5.
15. Muriel-Sánchez JM, Coheña-Jiménez M, Montaña-Jiménez P. Effect of phenol application time in the treatment of onychocryptosis: a randomized double-blind clinical trial. *Int J Environ Res Public Health* 2021;18:10478.
16. Bostancı S, Koçyiğit P, Güngör HK, Parlak N. Complications of sodium hydroxide chemical matrixectomy: nail dystrophy, allodynia, hyperalgesia. *J Am Podiatr Med Assoc* 2014;104:649-51.
17. Barreiro KN, Moradi M, Merrill T, Losito J, Southerland C, Buckley B. Healing efficacy and participant outcomes of chemical matrixectomies using a hydrogel containing oakain. *J Am Podiatr Med Assoc* 2014;104:617-21.
18. Ma H. Six steps to standardize the surgical approach for ingrown toenail. *An Bras Dermatol*. 2021;96:47-50.
19. Harrer J, Schöffl V, Hohenberger W, Schneider I. Treatment of ingrown toenails using a new conservative method: a prospective study comparing brace treatment with Emmert's procedure. *J Am Podiatr Med Assoc*. 2005;95:542-9.
20. Unal E, Yuksekdog S. A fast and effective solution for ingrown toenail: Creation of a 2-mm space between tissue and nail by sutureless lateral longitudinal excision. *Arch Dermatol Res*. 2021;313:799-803.
21. Kuru I, Sualp T, Ferit D, Gunduz T. Factors affecting recurrence rate of ingrown toenail treated with marginal toenail ablation. *Foot Ankle Int*. 2004;25:410-3.