

# Hamatometacarpal Fracture-Dislocations: Clinical Evaluation, Treatment Strategies, and Outcomes

✉ Melih Ünal<sup>1</sup>, ✉ Hanife Hale Hekim<sup>2</sup>, ✉ Cemal Hasoğlan<sup>1</sup>, ✉ Hasan May<sup>1</sup>, ✉ Baver Acar<sup>1</sup>

<sup>1</sup>University of Health Sciences Turkey, Antalya Training and Research Hospital, Clinic of Orthopedics and Traumatology, Antalya, Turkey

<sup>2</sup>University of Health Sciences Turkey, Antalya Training and Research Hospital, Clinic of Physical Therapy and Rehabilitation, Antalya, Turkey

## Abstract

**Objective:** Hamatometacarpal fracture-dislocations (HMFD) are rare hand injuries resulting from axial loading. This study aimed to present the clinical presentation and outcomes of HMFD, which is rare and likely to be missed in the emergency department.

**Methods:** A retrospective analysis of 15 patients who underwent surgical intervention for HMFD between 2015 and 2023 was conducted. At the last follow-up, the presence of union, malunion, residual subluxation, and Kellgren-Lawrence grading scale were evaluated. Time to diagnosis, time to return to work (RTW), level of difficulty in working, grip strength, and disabilities of the arm, shoulder, and hand (DASH) scores were evaluated.

**Results:** The mean patient age was 30.6 years. Most injuries (93.3%) were due to punching. Open reduction was performed in 73.3% of cases. No complications were reported during the mean of 52.3-month follow-up. Open reduction was associated with a lower DASH scores. Hand-intensive work was correlated with a longer time to RTW and higher difficulty to RTW. Delayed diagnosis was correlated with worse grip strength, but not with significantly different DASH scores.

**Conclusion:** HMFD is a rare hand injury that presents as a diagnostic challenge. Achieving anatomical reduction is crucial for restoring hand function. Therefore, comprehensive treatment strategies should be planned individually, taking into account patients's injury patterns.

**Keywords:** Hamate, metacarpal bones, fracture-dislocation, grip strength, hand injuries

## INTRODUCTION

Hamatometacarpal fracture-dislocation (HMFD) is a complex and challenging injury involving fracture and dislocation at the critical junction of the hamate and carpal bones of the hand. The anatomical region plays a crucial role in the function of the hand, and injuries in this area are particularly serious. Notably rare, HMFD typically result from traumatic events, such as falls, sports injuries, or direct strikes to the hand (1-4).

The combination of fracture and dislocation in this specific anatomical region can result in significant pain, swelling, and hand function loss. Ensuring an accurate diagnosis and appropriate treatment are essential to mitigate potential long-term complications and to facilitate an optimal recovery

process. Diagnosing this rare injury is also challenging and can be easily missed in the emergency department when clinical and radiographic images are available (3,5). Undiagnosed HMFD may present with chronic joint dislocation, such as weak hand strength, chronic pain, and advanced osteoarthritis (6-8).

Although stable HMFDs can be treated with a circular cast after reduction is achieved with appropriate manipulation, unstable HMFDs require open reduction and internal fixation (1,3,5,6). Open reduction may be required in missed cases, and treatment with proximal metacarpal resection, carpometacarpal arthrodesis (CMC-A), or interposition arthroplasty may be required in cases in which open reduction is inadequate (2). The aim of this study was to present the clinical presentation and



**Address for Correspondence:** Melih Ünal, University of Health Sciences Turkey, Antalya Training and Research Hospital, Clinic of Orthopedics and Traumatology, Antalya, Turkey  
**Phone:** +90 505 527 80 02 **E-mail:** melih.unal@gmail.com **ORCID ID:** orcid.org/0000-0002-8002-6408

**Received:** 16.05.2024  
**Accepted:** 18.07.2024

**Cite this article as:** Ünal M, Hekim HH, Hasoğlan C, May H, Acar B. Hamatometacarpal Fracture-Dislocations: Clinical Evaluation, Treatment Strategies, and Outcomes. Eur Arch Med Res. 2024;40(2):114-120



Copyright© 2024 The Author. Published by Galenos Publishing House on behalf of Prof. Dr. Cemil Taşcıoğlu City Hospital. This is an open access article under the Creative Commons AttributionNonCommercial 4.0 International (CC BY-NC 4.0) License.

outcomes of HMFds, which are rare and likely to be missed in the emergency department.

## METHODS

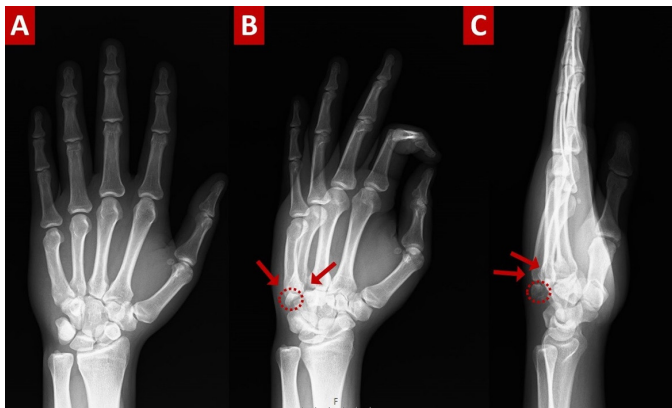
### Patients

Eighteen patients who were treated for HMFd between 2015 and 2023 were retrospectively reviewed. Patients who previously underwent hand surgery, had an inappropriated radiograph, were under 18 years of age, and had a follow-up duration of less than 1 year were excluded. The current study included 15 patients (mean age  $30.6 \pm 6.9$  years) who underwent surgery for HMFd. Preoperative radiographs and computed tomography (CT) images were obtained from hospital picture archiving and communication system (Figure 1,2). The time to diagnosis was noted from the hospital database. The University of Health

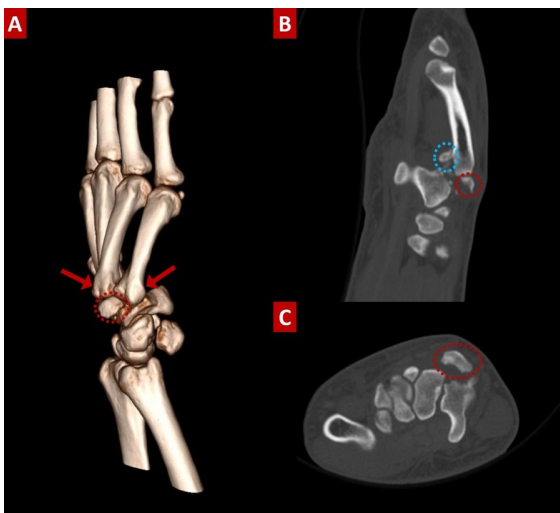
Sciences Turkey, Antalya Training and Research Hospital Clinical Research Ethics Committee approved the study protocol (decision number: 3/9, date: 21.03.2024). This study was conducted in accordance with the tenets of the Declaration of Helsinki, and informed consent was obtained from all patients.

### Surgical Technique

The same surgical team performed all procedures under general or regional anesthesia. 2 g of cefazolin was administered for surgical prophylaxis before surgery. First, closed reduction was performed, and reduction was checked using fluoroscopy in cases that were considered as a stable injury preoperatively. If concentric reduction was obtained, it was fixed using Kirschner wires (K-wire). If unstable injury was considered preoperatively or concentric reduction was not obtained by closed reduction, open reduction was performed using the dorsal approach. The dorsal carpo-metacarpal (CMC) ligaments were repaired by suturing in all patients who underwent open reduction. Then, fixation was performed using K-wire, screw or plate depending on the size of the fragment (Figure 3,4). When the fragments were too small for fixation, dorsal soft tissue repair was performed, and a temporary K-wire was placed in the CMC joint (case 2,6,14). Additionally, CMC-A with plate was required in case 4 due to multiple comminutions of the fracture (Table 1).

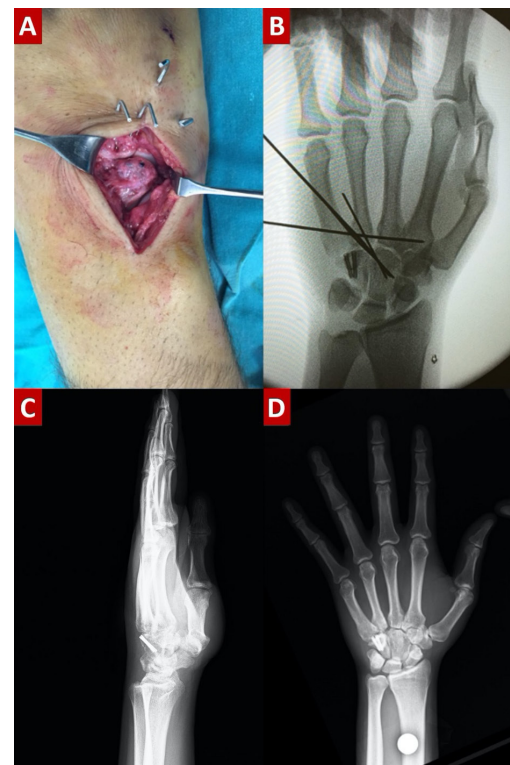


**Figure 1.** Preoperative anteroposterior (A), oblique (B), and lateral (C) radiographs of a 22-year-old male patient



**Figure 2.** Preoperative three-dimensional (A), sagittal (B), and axial (C) CT scans of patient. Red arrows: 4 and 5 CMC dislocation, red circle: Dorsal fragment of the coronal hamate fracture, blue circle: Comminution of 4 metacarpal basis

CT: Computed tomography, CMC: Carpo-metacarpal



**Figure 3.** Intraoperative images of the dorsal approach (A) and anteroposterior fluoroscopy image (B). Postoperative lateral (C) and anteroposterior images (D).

## Follow-up

The patients were immobilized in a cast for approximately 3 weeks. Metacarpophalangeal and interphalangeal range of motion (ROM) was allowed postoperatively. The K-wires were removed around 4 weeks. Strengthening exercises were initiated between 6 and 8 weeks.

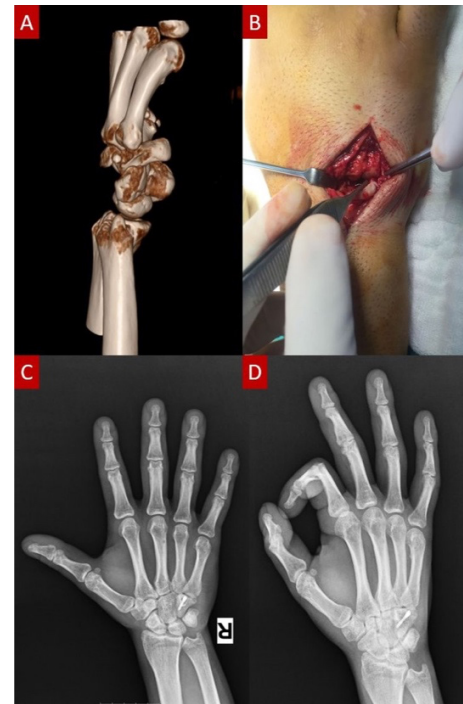
## Evaluation of Patients

All patients were evaluated clinically and radiologically. At the last follow-up, grip strength, and disabilities of the arm, shoulder, and hand (DASH) scores were assessed. Radiographs obtained during the final follow-up examination were utilized to evaluate the presence of union, malunion, residual subluxation, and Kellgren-Lawrence grading scale. Additionally, time to diagnosis, work, time to return to work (RTW), and difficulty in working were evaluated. If it was diagnosed before than 10 days it was noted as early diagnosis, otherwise it was noted as delayed diagnosis. The level of difficulty in working was assessed using patient responses categorized as “never”, “mild”, “hard”, or “unable”. Grip and fine hand skills required were defined as hand-intensive work (9).

## Statistical Analysis

Descriptive data were expressed as mean  $\pm$  standard deviation, median (minimum-maximum) for continuous variables, and number and frequency for categorical variables. As the group sample size was less than 50, the Shapiro-Wilk test was used to check for normality. The Mann-Whitney U test was used when the data did not follow a normal distribution, and the Student t-test

was used to analyze differences between the measurements of the two groups. Categorical variables were evaluated using the chi-square test. Pearson's correlation coefficient (PCC) was used to analyze relationship between the continuous variables followed a normal distribution. P-values less than 0.05 were considered statistically significant.



**Figure 4.** Preoperative three-dimensional scan (A) and intraoperative image of dorsal approach of patient (B). Postoperative anteroposterior (C) and oblique images (D) of patient

Case	Hamate	Treatment	4 <sup>th</sup> CMC	Treatment	5 <sup>th</sup> CMC	Treatment	Reduction
1	F	Screw	FD	KW	D	KW	Open
2	F	None	FD	KW	D	KW	Closed
3	F	KW	None	None	FD	KW	Closed
4	F	CMC-A	None	None	D	CMC-A	Open
5	None	None	FD	KW	FD	KW	Closed
6	F	None	FD	KW	FD	KW	Closed
7	F	Screw	FD	KW	D	KW	Open
8	F	Screw	FD	KW	D	None	Open
9	F	Screw	FD	KW	D	KW	Open
10	F	Screw	D	KW	D	None	Open
11	F	KW	FD	KW	FD	KW	Open
12	None	None	FD	KW	D	KW	Open
13	None	None	FD	KW	FD	KW	Open
14	F	None	D	KW	D	KW	Open
15	None	None	FD	KW	FD	KW	Open

CMC: Carpometacarpal, F: Fracture, KW: Kirschner wire, CMC-A: CMC arthrodesis with plate, FD: Fracture-dislocation, D: Dislocation

## RESULTS

All patients were male. The mean age was 30.6±6.9 (range, 18 to 45) years. Fourteen (93.3%) patients were right-handed, and 12 patients had a dominant-side fracture. The mean time to surgery was 17±30.6 (0-90). The injury mechanism consisted of 14 punching (93.3%) and 1 traffic accident (6.7%) (Table 2). Of the 15 cases, 11 (73.3%) underwent open reduction and 4 (26.7%) underwent closed reduction. The fracture configuration and fixation techniques were presented in Table 1. There were no complications. The mean follow-up was 52.3±32.5 (range, 12 to 102). The mean DASH score and grip strength were 21.1±8.9 and 81.7±19.5, respectively (Table 3).

Although the mean grip strength of the injured side was lower than that of the uninjured side, the difference was not statistically significant (p=0.580). While time to RTW was negatively correlated with grip strength (p=0.000, PCC =0.866), DASH score wasn't correlated (p=0.479; PCC=0.198). Although open or

closed reduction did not affect grip strength and osteoarthritis (p=0.966, p=0.295; respectively), the DASH score was lower in the open reduction group (p=0.966). Time to RTW and difficulty in working were worse in the hand-intensive work group (p=0.003, p=0.019; respectively). Time to diagnosis did not affect time to RTW and difficulty in work (p=0.580 and p=0.057, respectively) (Table 4). Although grip strength and DASH score were worse in the delayed diagnosis group, only grip strength was significantly different (p=0.001 and p=0.173, respectively).

## DISCUSSION

The results of this study revealed that HMFĐs often necessitate open reduction for optimal alignment and stability. Although closed reduction with K-wire fixation may be sufficient for simple fractures, more complex and comminuted injuries require meticulous planning and consideration of various fixation techniques to achieve and maintain concentric reduction. Delayed diagnosis is associated with poorer outcomes, such as

**Table 2. Descriptive data of the patients**

		n=15
Age, mean ± SD (min-max)		30.6±6.9 (18-45)
Sex, n (%)	Male Female	15 (100) 0 (0)
Side, n (%)	Right Left	13 (86.7) 2 (13.3)
Dominant side, n (%)	Right Left	14 (93.3) 1 (6.7)
Injury mechanism n (%)	Punching	14 (93.3)
	Traffic accident	1 (6.7)
Open fracture, n (%)		0
Time to diagnosis (days)		17±30.6 (0-90)
Follow-up (months)		52.3±32.5 (12-102)

SD: Standard deviation, min: Minimum, max: Maximum, n: Number of patients

**Table 3. Functional outcomes of patients**

DASH, mean ± SD (min-max)	21.1±8.9 (10.8-45)		
Grip strength, mean ± SD	Injured	Uninjured	p
	81.7±19.5	96.2±8.6	0.580 <sup>1</sup>
Grip strength, mean ± SD	Closed reduction	Open reduction	p
	81.4±11.9	81.9±22.1	0.966 <sup>1</sup>
DASH score, mean ± SD	29.9±17.9	17.9±5.5	0.014 <sup>1</sup>
Grip strength, mean ± SD	Early diagnosis	Delayed diagnosis	p
	93.3±5.3	64.3±20.3	0.001 <sup>1</sup>
DASH score, mean ± SD	18.5±6.3	25.0±11.3	0.173 <sup>1</sup>

DASH: Disabilities of the arm, shoulder, and hand, SD: Standard deviation, min: Minimum, max: Maximum, n: Number of patients  
<sup>1</sup>Independent sample t-test

Table 4. Evaluation of patients according to osteoarthritis and return to work						
Kellgren-Lawrence						
		1	2	3	4	p
Time to diagnosis (n)	Early	6	2	1	0	0.363 <sup>1</sup>
	Delayed	2	1	2	1	
Time to RTW Level of difficulty in work						
		Never	Mild	Hard	Unable	p
Time to diagnosis (n)	Early	6	3	0	0	0.057 <sup>1</sup>
	Delayed	1	5	0	0	
Hand intensive work (n)	No	6	2	0	0	0.019 <sup>1</sup>
	Yes	1	6	0	0	
Implant types (n)	Temporary	5	4	0	0	0.398 <sup>1</sup>
	Permanent	2	4	0	0	
CMC dislocation configuration (n)	4	1	1	0	0	0.875 <sup>1</sup>
	5	1	2	0	0	
	4-5	5	5	0	0	
Time to RTW (days)						
Time to diagnosis, mean ± SD	Early	Delayed				p
	6.1±1.5	6.8±3.4				0.580 <sup>2</sup>
Hand intensive work, Mean ± SD	No	Yes				p
	4.9±1.1	8.1±2.2				0.003 <sup>2</sup>
Implant types, mean ± SD	Temporary	Permanent				p
	6.9±2.8	5.6±1.4				0.343 <sup>2</sup>
CMC dislocation configuration, mean ± SD	4	5	4-5			p
	6.0±2.8	6.7±3.1	6.4±2.4			0.959 <sup>2</sup>

CMC: Carpometacarpal, RTW: Return to work n: Number of patients, SD: Standard deviation

<sup>1</sup>Pearson chi-square test, <sup>2</sup>Independent sample t-test

decreased grip strength and increased DASH scores. Furthermore, this study investigated the socioeconomic implications of HMFds, revealing that individuals engaged in hand-intensive work face challenges when returning to work.

Fracture-dislocation of the metacarpophalangeal joint is a very rare injury. The main mechanism of injury is axial loading. The degree of palmar flexion of the fifth metacarpal significantly affects the type of hamate injury. Substantial flexion can cause dorsal dislocation of the base of the fifth metacarpal, damage to the dorsal CMC ligament, and dorsal fracture of the hamate. A longitudinal coronal fracture of the hamate occurs with slight flexion of the fifth metacarpal. Fracture-dislocation was observed in 14 cases following punching and in one case following a traffic accident. Because both 4 and 5 are flexed during punching, the most common combination was both 4 and 5 CMC dislocations (66.6%), with the remainder comprising isolated 4 dislocations (13.3%) and isolated 5 CMC dislocations (20%). In addition, all patients had dorsal dislocation. According to the literature,

flexing the carpal bones is flexed during axial loading leads to dorsal dislocation, which is the most common dislocation (3,10). These results demonstrated that axial loading was the most prevalent mechanism of injury, consistent with the literature.

Diagnosing HMFds is challenging because of the limited diagnostic capability of anteroposterior and lateral radiographs during the initial evaluation (11). Therefore, a missed diagnosis is very frequently seen (3,12). The fourth and fifth CMC joints have a greater ROM than the second and third (13). Misdiagnosis and delayed treatment can therefore lead to complications such as malunion, residual subluxation, arthritis and functional impairment. Misdiagnosis and delayed treatment can lead to complications such as malunion, residual subluxation, arthritis, and functional impairments (6). Therefore, additional oblique views and CT scans are essential in suspected cases (3,14). In the current study, diagnosis was possible in only six patients at initial presentation in the emergency department. Three cases were diagnosed after orthopedic evaluation was conducted



within 3 days. In all cases, CT scan was required for diagnosis. The remaining six cases were diagnosed clinical suspicion caused from persistent symptoms during subsequent early and late follow-up assessments. Although radiography is limited in its ability to evaluate patients with HMF, CT is considered the gold standard. However, it should be noted that suspicion is the most crucial step in the diagnostic process. A delay in diagnosis is associated with poorer clinical outcomes (7,8). Delayed treatment causes prolonged immobility, difficulty in reduction, and increased requirement for open reduction (15). The current study demonstrated that delayed diagnosis may have a negative impact on grip strength and the DASH score. However, no relationship was found between time and diagnosis and difficulty with work or RTW.

Aim of the surgery is to achieve anatomic reduction of intra-articular fractures and concentric joint reduction. Inadequate treatment may cause malunion and residual subluxation (6). Although surgeons should prefer a suitable combination of reduction (open/closed) and fixation (K-wire, screw and plate) techniques, there is no consensus on an optimal treatment approach. The reduction can be achieved by both open and closed. However, it is difficult to maintain reduction with conservative treatment (14). Although open reduction and internal fixation techniques are commonly preferred in cases of delayed diagnosis, closed reduction and K-wire fixation is more commonly preferred in cases of early diagnosis, with isolated dislocations with or without comminuted small fragments. Closed reduction with K-wire fixation challenges to achieve concentric reduction by fluoroscopy. Therefore, it should be preferred for more stable fractures. Furthermore, it has been proposed that this approach may be preferable in cases diagnosed within the first 10 days (12). According to Lee et al.'s (16) treatment algorithm, hamate fractures with less than one-third articular surface involvement should be treated with closed reduction and K-wire fixation. Conversely, fractures exceeding one-third of the articular surface or those in the coronal plane should undergo open reduction and internal fixation by a dorsal approach (16). In the current study, open reduction was the most preferred approach (73.3%), and the latest closed reduction was performed at 14 days.

The treatment of an intra-articular fracture requires the achievement of anatomic reduction and rigid fixation. Screws are the optimal option for facilitating interfragmentary compression and rigid fixation. Headless screws and headed screws with or without a washer may be used (11). Unfortunately, there has been no compression study on the use of these screws in HMFs. Nevertheless, screws are more commonly preferred implants

in cases with sufficient bone stock for fixation (1,3,11,14,16). Although screws are a commonly employed method for the fixation of large fragments, comminution and fragment size may affect implant selection. In instances in which the fracture is too small and comminuted to be fixed, K-wires, washers, and buttress plates may be considered as a potential treatment option (11,17). Nevertheless, it has been proposed that the fracture morphology does not influence the selection of hardware, the size of the hardware, nor the use of washers (11). The dorsal buttress plate is particularly used for comminuted hamate fractures (17,18). This technique has several advantages. Although it provides a more rigid fixation in comminuted fractures, it doesn't fix the CMC joint. It therefore allows an early mobilization. However, it has some complications, including loss of sensation, formation of painful neuroma, and loss of motion due to extensor tendon adhesions or injury. Implant removal may be required due to implant-related pain (17).

In the current study, the most commonly used implants were screws for hamate fractures and K-wires for metacarpal fractures. K-wires were removed around the 4<sup>th</sup> week. Although some authors in the literature recommend that ligament injuries require at least six weeks for healing (19,20), the time required for K-wire removal varies between four and twelve, according to the literature (11,18-21). These injuries often involve a combination of bone and soft tissue injuries. Bone fixation combined with soft tissue repair provides significant stability. Furthermore, no loss of reduction or residual instability was observed in relation to the timing of K-wire removal in the present study. It is important to note that prolonged K-wire fixation can have a negative impact on hand movement (21). Therefore, it is not necessary to adopt overly aggressive approaches. No complications or reoperations were experienced in the current series. Although pain, stiffness, decreased grip strength, CMC subluxation, arthritis, malunion, nonunion, avascular necrosis, and nerve injury have been defined as complications in the literature, such complications are rare (1,4,11). Furthermore, they can be frequently aggravated by delayed diagnosis or inadequate rehabilitation (4,7,8). Although the current study demonstrated that delayed diagnosis was more likely to result in post-traumatic osteoarthritis, the current study has demonstrated that the difference was not statistically significant (Table 4).

HMF usually has good prognosis and functional outcomes (1,3,11,14). However, comminuted fracture, post-traumatic deformity, and delayed diagnosis lead to poor outcomes (3,22). The results of the current study are similar to those of the literature. Cases performed open reduction had worse DASH score and delayed diagnosed cases lower grip strength.

Similar to the current study, it has been shown that patients with HMFDF have a decrease in work activities (21). Furthermore, the current study revealed that hand intensive workers experienced greater difficulties in working and returning to work than others.

### Study Limitations

This study's main limitation is its retrospective design. Furthermore, the sample is heterogeneous regarding treatment and injury configurations. However, it is one of the largest case series in comparison to the number of cases in the literature. Additionally, this is the first time comprehensive analyses, such as assessments of the impact of injury on RTW, have been performed.

## CONCLUSION

HMFDF are very rare injuries with a high probability of being overlooked. Missed and delayed diagnosis will lead to functional disability in the hand, chronic pain, arthrosis and medico-legal problems. In cases of severe pain focusing on the hamatometacarpal joint following suspected trauma, the HMFDF should be kept in mind and the most appropriate fixation technique for each injury should be planned.

### Ethics

**Ethics Committee Approval:** The University of Health Sciences Turkey, Antalya Training and Research Hospital Clinical Research Ethics Committee approved the study protocol (decision number: 3/9, date: 21.03.2024).

**Informed Consent:** This study was conducted in accordance with the tenets of the Declaration of Helsinki, and informed consent was obtained from all patients.

### Authorship Contributions

Surgical and Medical Practices: H.M., B.A., Concept: M.Ü., B.A., Design: H.M., B.A., Data Collection or Processing: M.Ü., H.H.H., C.H., H.M., Analysis or Interpretation: M.Ü., H.M., Literature Search: M.Ü., H.H.H., C.H., Writing: M.Ü., H.H.H., C.H., B.A.

**Conflict of Interest:** No conflicts of interest were declared by the authors.

**Financial Disclosure:** The authors declared that this study received no financial support.

## REFERENCES

- Hirano K, Inoue G. Classification and treatment of hamate fractures. *Hand Surg.* 2005;10:151-7.
- Green DP, Hotchkiss RN, Pederson WC, Wolfe SW, Cohen MS. *Green's Operative Hand Surgery.* 7th ed. Elsevier; 2017:244-5.
- Kural C, Başaran SH, Ercin E, Bayrak A, Bilgili MG, Baca E. Fourth and fifth carpometacarpal fracture dislocations. *Acta Orthop Traumatol Turc.* 2014;48:655-60.
- Price MB, Vanorny D, Mitchell S, Wu C. Hamate Body Fractures: A Comprehensive Review of the Literature. *Curr Rev Musculoskelet Med.* 2021;14:475-84.
- Fisher MR, Rogers LF, Hendrix RW. Systematic approach to identifying fourth and fifth carpometacarpal joint dislocations. *AJR Am J Roentgenol.* 1983;140:319-24.
- Ebraheim NA, Skie MC, Savolaine ER, Jackson WT. Coronal fracture of the body of the hamate. *J Trauma.* 1995;38:169-74.
- Terrono A, Ferenz CC, Nalebuff EA. Delayed diagnosis in nonunion of the body of the hamate: a case report. *J Hand Surg.* 1989;14:329-31.
- Thomas AP, Birch R. An unusual hamate fracture. *Hand.* 1983;15:281-6.
- Eliasson K, Fjellman-Wiklund A, Dahlgren G, Hellman T, Svartengren M, Nyman T, et al. Ergonomists' experiences of executing occupational health surveillance for workers exposed to hand-intensive work: a qualitative exploration. *BMC Health Serv Res.* 2022;22:1223.
- de Beer JD, Maloon S, Anderson P, Jones G, Singer M. Multiple carpometacarpal dislocations. *J Hand Surg Br.* 1989;14:105-8.
- Verhies SHWL, Knaus WJ, Simeone FJ, Mudgal CS. Carpometacarpal 4/5 Fracture Dislocations: Fracture Morphology and Surgical Treatment. *J Hand Microsurg.* 2020;12:S21-7.
- Henderson JJ, Arafa MA. Carpometacarpal dislocation. An easily missed diagnosis. *J Bone Joint Surg Br.* 1987;69:212-4.
- El-Shennawy M, Nakamura K, Patterson RM, Viegas SF. Three-dimensional kinematic analysis of the second through fifth carpometacarpal joints. *J Hand Surg Am.* 2001;26:1030-5.
- Cain JE, Shepler TR, Wilson MR. Hamatometacarpal fracture-dislocation: classification and treatment. *J Hand Surg.* 1987;12:762-7.
- Luangjarmekorn P, Nitayavardhana S, Kuptniratsaikul V, Pataradool K, Kitidumrongsook P. Effect of delayed distal radius fracture fixation on the difficulty of surgical operation. *Heliyon.* 2022;8:e11772.
- Lee SU, Park JJ, Kim HM, Jeong C, Oh JR. Fourth and fifth carpometacarpal fracture and dislocation of the hand: new classification and treatment. *Eur J Orthop Surg Traumatol.* 2012;22:571-8.
- Tan ES, Tay SC. Dorsal Buttress Plate Fixation of Ulnar Carpometacarpal Joint Fracture Dislocations. *Tech Hand Up Extrem Surg.* 2016;20:77-82.
- Iwata N, Komura S, Hirakawa A, Kanamori S, Masuda T, Ito Y, et al. Dorsal buttress plate fixation for the treatment of fracture-dislocation of the fifth carpometacarpal joint with avulsion fracture of the hamate: a case report. *Arch Orthop Trauma Surg.* 2019;139:135-9.
- Jerome JTJ. Metacarpal and phalangeal fractures and fractures-dislocations. Slullitel P, Rossi L, Gastón Camino-Willhuber G, editors. *Orthopaedics and Trauma.* Springer; Cham. 2024.
- Talmaç MA, Görgel MA, Dırvar F, Tok O, Özdemir HM. Functional and radiological outcomes of multiple dorsal carpometacarpal fracture dislocations treated with open reduction and internal fixation. *Eklem Hastalik Cerrahisi.* 2019;30:130-6.
- Ercan N, Arican G, Elci MC, İltar S, Alemdaroğlu KB. Outcomes of Headless Screw Fixation for Coronal Hamate Fractures. *Hand Microsurg.* 2024;13:28-34.
- Lawlis JF 3rd, Gunther SF. Carpometacarpal dislocations. Long-term follow-up. *J Bone Joint Surg Am.* 1991;73:52-9.